

# Advances in Pulmonary Hypertension

Vol 18, No 4; 2019

Official Journal of the Pulmonary Hypertension Association

## Pulmonary Hypertension: Every Picture Tells a Story

What Echocardiography Can Reliably Tell Us About Our Pulmonary Hypertension Patients

*Natasha A. Vedage, MD; Anjali Vaidya, MD, FACC, FASE, FACP*

Multimodality Imaging of Pulmonary Hypertension

*Seth Kligerman, MD; Michael Horowitz, MD, PhD; Lewis Hahn, MD; Albert Hsiao, MD, PhD; Elizabeth Weihe, MD*

The Future of Imaging in Pulmonary Hypertension: Better Assessment of Structure, Function, and Flow

*Akshil Narang, MD; Benjamin H. Freed, MD*

Pulmonary Hypertension Roundtable: The Present and Future of Imaging in Pulmonary Hypertension

*Jeffrey D. Edelman, MD; Harrison W. Farber, MD; Benjamin H. Freed, MD; Paul Hassoun, MD; Peter Leary, MD, PhD; Sudhakar N.J. Pipavath, MD; Anjali Vaidya, MD, FACC, FASE, FACP*

Ask the Expert: Radiographic Signs and Patterns of Pulmonary Hypertension: A Pictorial Essay

*Hugo Carmona, MD; Wei Wu, MD; Sudhakar N.J. Pipavath, MD*

PH Grand Rounds: When a Clot Is Not a Clot: An Unusual Cause of Progressively Worsening Dyspnea in a Previously Healthy Woman

*Nicholas Fox, MD; Victor Test, MD; Vinod Jona, MD; Russell Harley, MD; Rabul G. Argula, MD*

PH Professional Network: Facilitating and Improving Adherence: The Development of a Pulmonary Arterial Hypertension Self-Care Management Agreement

*Jacqueline M. Brewer, AGPCNP-BC; Samuel A. Allen, DO, FCCP*

## Advances In Pulmonary Hypertension Editorial Advisory Board

### *Editor-in-Chief*

**Deborah Jo Levine, MD**  
Professor of Medicine, Pulmonary and Critical Care  
Medical Director Lung Transplantation  
Director of Pulmonary Hypertension  
University of Texas Health Science Center  
San Antonio, TX

### *Immediate Past Editor-in-Chief*

**Harrison W. Farber, MD**  
Professor of Medicine  
Tufts University School of Medicine  
Boston, MA

### *Editor-in-Chief Elect*

**Sean M. Studer, MD, MSc**  
Chief of Medicine  
Woodhull Medical Center  
New York University  
New York, NY

### *Associate Editor*

**Jeffrey D. Edelman, MD**  
Associate Professor of Medicine  
Pulmonary and Critical Care Division  
University of Washington  
VA Puget Sound Health Care System  
Seattle, WA

**D. Dunbar Ivy, MD**  
Professor of Pediatrics  
University of Colorado  
Selby's Chair in Pediatric Cardiology  
Children's Hospital Colorado  
Denver, CO

**Richard Krasuski, MD**  
Professor of Medicine  
Director of the Adult Congenital Heart Disease Center  
Director of Hemodynamic Research  
Duke University Medical Center  
Durham, NC

**Ioana R. Preston, MD**  
Pulmonary Function Lab Director  
Director, Pulmonary Hypertension Center  
Tufts Medical Center  
Associate Professor, Tufts University School of Medicine  
Boston, MA

### *International Editor*

**Marc Humbert, M., PhD**  
Director, French Pulmonary Hypertension Reference Center  
South Paris University  
Professor of Medicine  
Paris, France

### *Editorial Board*

**Anna Hennes, MD**  
Associate Professor of Medicine  
Assistant Director, Pulmonary Vascular Center  
Vanderbilt University  
Nashville, TN

**Usha Krishnan, MD**  
Professor of Pediatrics  
Columbia University Vagelos College of Physicians and Surgeons  
Associate Director, Pulmonary Hypertension Center  
Columbia University Irving Medical Center  
New York, NY

**Nick Morrell, MD, ScD, FMedSci**  
Professor of Cardiopulmonary Medicine  
University of Cambridge  
Cambridge, United Kingdom

**Jonathan Rich, MD**  
Associate Professor in Medicine-Cardiology  
Northwestern University Feinberg School of Medicine  
Advanced Heart Failure and Transplant Cardiologist  
Northwestern Memorial Hospital  
Chicago, IL

**John J. Ryan, MD, FACC, FAHA**  
Associate Professor, Department of Medicine  
Director, Pulmonary Hypertension Center  
University of Utah  
Salt Lake City, UT

**Oksana A. Shlobin, MD**  
Associate Professor, Georgetown University School of Medicine  
Assistant Clinical Professor of Medicine, Virginia Commonwealth University  
Co-Director, Pulmonary Vascular Disease Program  
Director of Education, Advanced Lung Disease and Transplant Program  
Inova Fairfax Hospital  
Falls Church, VA

**Anjali Vaidya, MD, FACC, FASE, FACP**  
Associate Professor, Medicine  
Associate Director, Pulmonary Hypertension, Right Heart Failure and CTEPH Program  
Temple University  
Philadelphia, PA

### *PHPN Section Editor*

**Traci Houston, RN, MS**  
The Johns Hopkins Pulmonary Hypertension Program  
Johns Hopkins University  
Baltimore, MD

## Program Description

The mission of *Advances in Pulmonary Hypertension* is to serve as the premiere forum for state-of-the-art information regarding diagnosis, pathophysiology, and treatment of pulmonary hypertension (PH). The 2018 Nice revision of the World Symposium on Pulmonary Hypertension (Simmonneau G, Montani D, Celermajer DS, et al. Haemodynamic definitions and updated clinical classification of pulmonary hypertension. *Eur Respir J*. 2019;53(1). DOI:10.1183/13993003.01913-2018) serves as a guide to categories of PH addressed in *Advances in Pulmonary Hypertension*. While focusing on Group 1 PH (PAH: pulmonary arterial hypertension), the other categories (Group 2, PH due to left heart disease; Group 3, PH due to lung diseases and/or hypoxia; Group 4, PH due to pulmonary artery obstructions; Group 5, PH with unclear and/or multifactorial mechanisms) are also addressed. This mission is achieved by a combination of invited review articles, roundtable discussions with panels consisting of international experts in PH, and original contributions.

## Objectives

- Provide up-to-date information regarding diagnosis, pathophysiology, and treatment of PH.
- Serve as a forum for presentation and discussion of important issues in the field, including new paradigms of disease understanding and investigational trial design.

## The Scientific Leadership Council of the Pulmonary Hypertension Association

The scientific program of the Pulmonary Hypertension Association is guided by PHA's Scientific Leadership Council. The Council includes the following health care professionals.

**Ronald J. Oudiz, MD**  
*Chair*  
Professor of Medicine  
Director, Liu Center for Pulmonary Hypertension  
LA Biomedical Research Institute at Harbor – UCLA  
Medical Center  
Torrance, CA

**Murali M. Chakinala, MD, FCCP**  
*Chair-Elect*  
Professor of Medicine  
Washington University School of Medicine  
Division of Pulmonary and Critical Care  
St. Louis, MO

**Erika S. Berman Rosenzweig, MD**  
*Immediate Past Chair*  
Professor of Pediatrics (in Medicine)  
Columbia University Vagelos College of Physicians and Surgeons  
Columbia University Irving Medical Center  
New York, NY

**Steven H. Abman, MD**  
Professor, Department of Pediatrics  
Director, Pediatric Heart Lung Center  
University of Colorado School of Medicine  
Children's Hospital Colorado  
Aurora, CO

**William R. Auger, MD**  
Clinical Professor of Medicine  
Lewis Katz School of Medicine at Temple University  
Physician, Pulmonary Hypertension, Right Heart Failure and CTEPH Program  
Temple Heart and Vascular Institute  
Philadelphia, PA

**Sonja Bartolome, MD**  
Associate Professor, Internal Medicine  
Director, Liver Transplant Critical Care  
University of Texas Southwestern Medical Center  
Dallas, TX

**Todd M. Bull, MD**  
Professor of Medicine  
Director, Pulmonary Vascular Disease Center  
Director, Comprehensive Lung and Breathing Program  
Associate Head of Clinical Affairs  
Pulmonary Sciences and Critical Care Medicine and Cardiology  
University of Colorado  
Denver, CO

**Kelly Chin, MD**  
Associate Professor, Internal Medicine  
Director, Pulmonary Hypertension Program  
University of Texas Southwestern Medical Center  
Dallas, TX

**Lorinda Chung, MD**  
Assistant Professor of Medicine  
Stanford University  
Palo Alto, CA

**Vinicio A. de Jesus Perez, MD, FCCP, FAHA**  
Associate Professor of Medicine  
Co-Director, Stanford Translational Investigator Program  
Stanford Adult Pulmonary Hypertension Clinic  
Division of Pulmonary and Critical Care Medicine  
Stanford University Medical Center  
Stanford, CA

**Teresa De Marco, MD**  
Professor of Medicine  
Director of Advanced Heart Failure and Pulmonary Hypertension  
Medical Director of Heart Transplantation  
University of California, San Francisco  
San Francisco, CA

**Ankit A. Desai, MD, FACC, FAHA**  
Associate Professor of Medicine  
Indiana University School of Medicine  
Indianapolis, IN

**Jeffrey R. Fineman, MD**  
Professor of Pediatrics  
Pediatric Critical Care Specialist  
Critical Care Division Chief  
University of California, San Francisco  
Benioff Children's Hospital  
San Francisco, CA

**Robert P. Frantz, MD**  
Director, Pulmonary Hypertension Clinic  
Professor of Medicine  
Mayo Clinic  
Rochester, MN

**Mardi Gombert-Maitland, MD, MSc**  
Director of the Pulmonary Hypertension Program  
Medical Faculty Associates  
George Washington University, Heart and Vascular Institute  
Washington, DC

**Anna Hennes, MD**  
Associate Professor of Medicine  
Assistant Director, Pulmonary Vascular Center  
Vanderbilt University  
Nashville, TN

**Steven Kawut, MD, MS**  
Professor of Medicine and Epidemiology  
Director, Pulmonary Vascular Disease Program  
Perelman School of Medicine at the University of Pennsylvania  
Philadelphia, PA

**Tim Lahm, MD**  
Associate Professor of Medicine and Cellular & Integrative Physiology  
Division of Pulmonary, Critical Care, Sleep and Occupational Medicine  
Indiana University School of Medicine  
Indianapolis, IN

**Deborah Jo Levine, MD**  
Professor of Medicine, Pulmonary and Critical Care

Medical Director Lung Transplantation  
Director of Pulmonary Hypertension  
University of Texas Health Science Center  
San Antonio  
San Antonio, TX

**Roberto F. Machado, MD**  
Dr. Calvin H. English Professor of Medicine  
Chief, Division of Pulmonary, Critical Care, Sleep, and Occupational Medicine  
Indiana University Department of Medicine  
Indianapolis, IN

**Lana Melendres-Groves, MD**  
Medical Director, Pulmonary Hypertension Program  
Associate Professor, Department of Internal Medicine  
Pulmonary and Critical Care Division  
University of New Mexico  
Albuquerque, NM

**John J. Ryan, MD, FACC, FAHA**  
Associate Professor, Department of Medicine  
Director, Pulmonary Hypertension Center  
University of Utah  
Salt Lake City, UT

**Jeffrey S. Sager, MD, MSCE**  
Director, Cottage Pulmonary Hypertension Center  
Santa Barbara Pulmonary Consultants  
Santa Barbara, CA

**Oksana A. Shlobin, MD, FCCP**  
Co-Director, Pulmonary Vascular Disease Program  
Director of Education, Advanced Lung Disease and Transplant Program  
Inova Fairfax Hospital  
Falls Church, VA

**Thenappan Thenappan, MD**  
Associate Professor of Medicine, Cardiovascular Division  
University of Minnesota  
Minneapolis, MN

**Corey E. Ventetuo, MD, MS**  
Associate Professor of Medicine and Health Services, Policy, and Practice, The Warren Alpert Medical School of Brown University  
Associate Director, Pulmonary Hypertension Center  
Medical Director, Adult Extracorporeal Life Support Program  
Director of Clinical Research, Pulmonary Division  
Rhode Island Hospital  
Providence, RI

**Timothy L. Williamson, MD**  
Associate Professor of Medicine  
Director, Center for Pulmonary Arterial Hypertension  
University of Kansas Medical Center  
Kansas City, KS

**Delphine Yung, MD**  
Associate Professor  
Center for Clinical and Translational Research  
Seattle Children's Hospital  
Seattle, WA

**Liaisons**  
**Cheri Abbott, RN, CCRP**  
*PH Professional Network Liaison*  
Chair-Elect, PH Professional Network  
University of Colorado School of Medicine  
Denver, CO

**Nicole Reid, RN, BSN, DABAT**  
*Patient Liaison*  
Reston, VA

**Fran Rogers, MSN, CRNP**  
*PH Professional Network Liaison*  
Chair, PH Professional Network  
Temple University Hospital  
Philadelphia, PA

**Distinguished Advisors**  
**David B. Badesch, MD**  
Professor of Medicine  
Clinical Director, Pulmonary Hypertension Center  
University of Colorado Health Sciences Center  
Aurora, CO

**Bruce Brundage, MD**  
Professor of Medicine Emeritus  
David Geffen School of Medicine at UCLA  
Bend, OR

**Richard N. Channick, MD**  
Physician, Pulmonary and Critical Care Medicine  
Ronald Reagan UCLA Medical Center  
Los Angeles, CA

**C. Gregory Elliott, MD**  
Professor of Medicine  
University of Utah School of Medicine  
Murray, UT

**Karen A. Fagan, MD**  
Chief of Pulmonology, Critical Care  
Professor of Internal Medicine and Pharmacology  
University of South Alabama  
Mobile, AL

**Michael D. McGoan, MD**  
Professor Emeritus of Medicine  
Mayo Clinic  
Rochester, MN

**Vallerie V. McLaughlin, MD**  
Director, Pulmonary Hypertension Program  
Kim A. Eagle, MD, Endowed Professor in Cardiovascular Medicine  
University of Michigan CVC Cardiovascular Medicine  
Ann Arbor, MI

**John H. Newman, MD**  
Elsa S. Hanigan Chair in Pulmonary Medicine  
Professor of Medicine  
Vanderbilt University School of Medicine  
Director, Pulmonary & Critical Care Fellowship Program  
Nashville, TN



## PUBLISHER

Pulmonary Hypertension Association  
Brad A. Wong, President and CEO

## PHA OFFICE

Pulmonary Hypertension Association  
801 Roeder Road, Ste. 1000  
Silver Spring, MD 20910  
301-565-3004; 301-565-3994 (fax)  
Advances@PHAssociation.org

## PUBLISHING OPERATIONS

Clarissa Nemeth,  
Managing Editor  
Allen Press, Inc.

Copyright ©2019 by Pulmonary Hypertension Association. All rights reserved. None of the contents may be reproduced in any form whatsoever without the written permission of PHA.

*Advances in Pulmonary Hypertension* is available online at [www.AdvancesinPH.org](http://www.AdvancesinPH.org).

*Advances in Pulmonary Hypertension* is directed to cardiologists, pulmonologists, rheumatologists, pediatricians, internists, and other health care professionals involved in the treatment of patients with PH.

*Advances in Pulmonary Hypertension: Official Journal of the Pulmonary Hypertension Association* is a quarterly publication directed by an editorial board of renowned pulmonary hypertension (PH) experts with oversight by PHA's Scientific Leadership Council. The mission of *Advances in PH* is to assist physicians in their clinical decision-making by informing them of important trends affecting their practice and providing an analysis of the impact of new findings and current information in peer-reviewed publications. Each article is reviewed and approved by members of the Editorial Board.

While most articles are invited by the Editorial Board, the following submissions will be considered for publication:

- Reviews that summarize and synthesize peer-reviewed literature to date on relevant topics
- Letters to the Editor
- Clinical case studies

Submitted manuscripts are reviewed by the Editorial Board and other experts in the field. Acceptance of manuscripts is determined by factors such as quality, relevance, and perceived value to clinical decision-making.

## CONTENTS

- 109 Editor's Memo  
*Deborah Jo Levine, MD*
- 109 Guest Editors' Memo  
*Jeffrey D. Edelman, MD; Harrison W. Farber, MD*
- 110 What Echocardiography Can Reliably Tell Us About Our Pulmonary Hypertension Patients  
*Natasha A. Vedage, MD; Anjali Vaidya, MD, FACC, FASE, FACP*
- 115 Multimodality Imaging of Pulmonary Hypertension  
*Seth Kligerman, MD; Michael Horowitz, MD, PhD; Lewis Hahn, MD; Albert Hsiao, MD, PhD; Elizabeth Weihe, MD*
- 126 The Future of Imaging in Pulmonary Hypertension: Better Assessment of Structure, Function, and Flow  
*Akhil Narang, MD; Benjamin H. Freed, MD*
- 134 Pulmonary Hypertension Roundtable: The Present and Future of Imaging in Pulmonary Hypertension  
*Jeffrey D. Edelman, MD; Harrison W. Farber, MD; Benjamin H. Freed, MD; Paul Hassoun, MD; Peter Leary, MD, PhD; Sudhakar N.J. Pipavath, MD; Anjali Vaidya, MD, FACC, FASE, FACP*
- 141 Ask the Expert: Radiographic Signs and Patterns of Pulmonary Hypertension: A Pictorial Essay  
*Hugo Carmona, MD; Wei Wu, MD; Sudhakar N.J. Pipavath, MD*
- 152 PH Grand Rounds: When a Clot Is Not a Clot: An Unusual Cause of Progressively Worsening Dyspnea in a Previously Healthy Woman  
*Nicholas Fox, MD; Victor Test, MD; Vinod Jona, MD; Russell Harley, MD; Rahul G. Argula, MD*
- 157 PH Professional Network: Facilitating and Improving Adherence: The Development of a Pulmonary Arterial Hypertension Self-Care Management Agreement  
*Jacqueline M. Brewer, AGPCNP-BC; Samuel A. Allen, DO, FCCP*

## *Advances in Pulmonary Hypertension's* Web Platform

*Advances in Pulmonary Hypertension* is available at [www.AdvancesinPH.org](http://www.AdvancesinPH.org). This site offers enhanced capabilities including a dedicated DOI and cross-referencing potential, as well as other features valuable to practitioners, researchers, and educators. Registration is recommended to access all site features and benefits.

### Benefits of Registration Include:

- A unique user profile that will allow you to manage your current subscriptions (including online access)
- The ability to create favorites lists down to the article level
- The ability to customize email alerts to receive specific notification about the topics you care most about

## EDITORS' MEMO

Welcome to a very special issue of *Advances in Pulmonary Hypertension* (PH). Drs Jeffrey D. Edelman and Harrison W. Farber have guest edited this unique issue of the journal which encompasses “all things imaging in PH.” It is the only full journal devoted to this topic and will be used as a reference in the PH world for years to come. One significant distinction between this issue and others is the inclusion of a multitude of leaders and experts from many fields: pulmonologists, cardiologists, radiologists, researchers, and echocardiographers. Drs Edelman and Farber have brought this multidisciplinary team together to bring us an exquisite all-encompassing knowledge base on this topic.

To begin the issue, Drs Natasha A. Vedage and Anjali Vaidya explore the role of echocardiography as a tool which will help not only to detect PH, but also to discriminate among the subgroups of PH when a patient is being evaluated. They discuss novel approaches using echocardiography that will help clinicians predict the hemodynamic profile of a patient as well as help define etiology and severity of PH.

Radiologists from the University of California at San Diego—Drs Seth Kligerman, Michael Horowitz, Lewis Hahn, Albert Hsiao, and Elizabeth Wei-

he—elucidate how imaging techniques play such an integral role in the workup of a patient with PH. The collaboration between radiologists and clinicians is imperative when assessing the pulmonary and systemic vasculature, heart, lungs, and mediastinum in order to make the correct diagnosis and manage the patient with PH.

Drs Akhil Narang and Benjamin H. Freed then discuss how novel techniques and advancements in current imaging techniques have provided the opportunity to extend imaging's role from diagnostics to enhancing risk stratification and providing additional phenotypic data that may alter therapeutic management.

In a special feature for our “Ask the Expert” section, Drs Hugo Carmona, Wei Wu, and Sudhakar N.J. Pipavath take us through a pictorial tour of imaging in PH. They consider radiographic signs in all types of imaging that can be used in identifying the etiology and severity of PH, presenting multiple examples of a variety of imaging features that can assist clinicians in distinguishing some of the clinical manifestations of PH.

In our PH Professional Network corner this month, Ms Jacqueline M. Brewer and Dr Samuel A. Allen discuss the importance of team-based care that

includes the patients themselves and their family as well as their health-care team. This section discusses how vital communication with all parts of the team is for the patients in terms of medication adherence, quality of life, and overall morbidity and mortality.

And of course, to round out this issue, Drs Edelman and Farber led an exceptional group of experts in the world of imaging for PH. Drs Benjamin H. Freed, Paul Hassoun, Peter Leary, Sudhakar N.J. Pipavath, and Anjali Vaidya convened to update us on the variable uses, benefits, and advances in radiographical techniques and echocardiography to diagnose and manage patients with PH.

This outstanding issue of *Advances* is an invaluable resource for all of us in the field of pulmonary vascular disease. Congratulations to Drs Edelman and Farber, as well as all of the contributors, on an excellent issue.

### **Deborah Jo Levine, MD**

Professor of Medicine, Pulmonary and Critical Care  
Medical Director Lung Transplantation  
Director of Pulmonary Hypertension  
University of Texas Health Science Center  
San Antonio  
San Antonio, TX

## GUEST EDITORS' MEMO

Every day, pulmonary hypertension (PH) is becoming a more multidisciplinary field. The area of imaging reflects this diversity and richness of expertise. From the simple chest x-ray to the latest magnetic resonance imaging, the data available from the images themselves combined with interpretation and evaluation in association with the computational and neural processing capabilities of machines and their masters are truly astounding.

Routine imaging with or without clinical suspicion may reveal the presence of PH and provide insight into its underlying causes and associated conditions. Ongoing refinements and innovations may further define progression, response

to therapy, and provide insight into disease prognosis and pathogenesis.

As the technology of medicine continues to explode, it is becoming even more tempting and convenient to read reports instead of viewing the actual studies. The experience is unfulfilling and uninformative—like looking at the notes of a song without hearing the music or reading a recipe without tasting the food. In this issue of *Advances in Pulmonary Hypertension*, we take advantage of the new digital format to provide a plethora of representative images selected, described, and interpreted by our esteemed authors. We explore the basic findings and nuances of PH imaging as interpreted through the eyes and minds

of radiologists, cardiologists, and pulmonologists. We hope you take advantage of this technology and spend time viewing the images in order to enhance your understanding of this disease entity.

### **Jeffrey D. Edelman, MD**

Associate Professor of Medicine  
Pulmonary and Critical Care Division  
University of Washington  
VA Puget Sound Health Care System  
Seattle, WA

### **Harrison W. Farber, MD**

Professor of Medicine  
Tufts University School of Medicine  
Boston, MA

# What Echocardiography Can Reliably Tell Us About Our Pulmonary Hypertension Patients

Natasha A. Vedage, MD  
*Temple University Lewis Katz School of  
Medicine  
Philadelphia, PA*

Anjali Vaidya, MD, FACC, FASE,  
FACP  
*Co-Director, Pulmonary Hypertension, Right  
Heart Failure, and CTEPH Program  
Advanced Heart Failure and Cardiac  
Transplant  
Temple University Lewis Katz School of  
Medicine  
Philadelphia, PA*

Pulmonary hypertension (PH) is a complex, multi-organ system disease that is broadly defined by an elevation in pulmonary artery pressures. There are key biologic differences in the pathophysiology among the different PH subgroups that warrant a targeted approach to clinical care of these patients. The complex geometry of and wide array of clinical tools to assess the right heart in PH add another layer of complexity in patient care. Echocardiography can be used as a powerful tool to discriminate among the subgroups of PH, a critical first step in evaluating a new case of PH. In this article, we will explore novel approaches using echocardiography that go beyond simply estimating pulmonary pressures and provide a readily accessible means of adding diagnostic and prognostic accuracy in the clinical setting.

## BACKGROUND

At the first World Symposium on Pulmonary Hypertension (WSPH) in 1973, pulmonary hypertension (PH) was defined as mean pulmonary arterial pressure (mPAP)  $\geq 25$  mm Hg measured by right heart catheterization (RHC) at rest.<sup>1</sup> At the sixth WSPH, which met in 2018, the aforementioned definition of PH was criticized for being too conservative and lacking specificity for identifying patients with pulmonary vascular disease (PVD) or precapillary PH.

In a systematic review of over 130 studies, Kovacs et al. showed that mPAP in the supine position at rest in healthy individuals was  $14.0 \pm 3.3$  mm Hg and rarely exceeded 20 mm Hg.<sup>2</sup> Therefore, the prior definition of PH (mPAP  $\geq 25$  mm Hg) was greater than 2 standard deviations higher than what is observed in healthy individuals and could miss patients with true PH. For this reason, the latest WSPH changed the definition of PH to  $\geq 20$  mm Hg. Another major limitation of the previous definition was its lack of ability to distinguish between patients with precapillary and postcap-

illary disease. For example, an elevated mPAP would identify both a patient with underlying chronic obstructive pulmonary disease who has evidence of PVD and a patient with PH due to heart failure with preserved left ventricular ejection fraction (LVEF), but we know that these patients have very different physiologic pathways at play and thus are managed quite differently from a PH perspective.

Finally, in the previous classification of PH subgroups, only Group 1 or pulmonary arterial hypertension (PAH) included pulmonary vascular resistance (PVR  $\geq 3$  Wood units [WU; mm Hg/L·min]) despite the fact that almost all subgroups can exhibit a precapillary phenotype characterized by an elevated PVR.

This led to the proposal by the sixth WSPH to include PVR  $\geq 3$  WU in the definition for all forms of precapillary PH.<sup>3</sup>

There are several important clinical implications for the changes proposed by the sixth WSPH. The lowering of the mPAP criterion to define PH could potentially increase the number of PH

patients referred for PH evaluation. In order to respond to a larger volume of patients being referred for PH evaluation, there must be readily accessible and validated tools to initially assess patients with suspected PH. Further, while RHC remains the “gold standard” for diagnosis, it is not always a practical tool for immediate accessibility and repeated measurements which are necessary in managing PH over time and in response to therapy. For this reason, novel echocardiographic measures that recapitulate invasive hemodynamics and even predict outcomes in PH represent a powerful tool in a clinician’s arsenal. While we acknowledge that echocardiography can be technically difficult due to the unique shape and geometry of the right heart, we sought to highlight echocardiographic measurements that are easy to perform and can accurately phenotype PH subgroups. Recognizing that there are multiple clinical factors that contribute to a patient’s presentation and ultimate prognosis, this review will focus on how echocardiography can be used to comprehensively assess patients with PH.

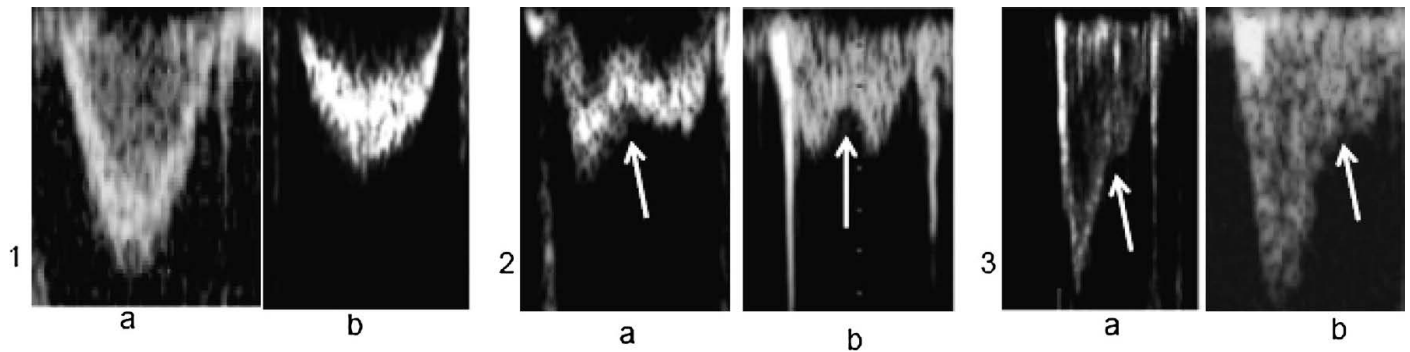
## ESTIMATING HEMODYNAMICS

PVD is defined by the presence of PVR  $> 3$  WU and normal to low left heart filling pressures. While RHC is required to make the diagnosis of PVD, it has

Key Words—pulmonary hypertension, pulmonary arterial hypertension, echocardiography, hemodynamics, TAPSE, RV morphology

Correspondence: anjali.vaidya@tuhs.temple.edu

Disclosure: The authors have no conflicts of interest to disclose.



**Figure 1:** Examples of the 3 distinct patterns appreciated in the flow velocity envelope obtained from pulsed-wave Doppler interrogation from the right ventricular outflow tract (FVE<sub>RVOT</sub>). (1a) and (1b) show representative Doppler tracings without evidence of Doppler notching (no notch group); note the envelope may be (a) parabolic or (b) somewhat triangular in shape. (2a) and (2b) show examples in the midsystolic notch group, characterized by a distinct notch or nadir in its mid portion, dividing the flow profile into 2 distinct peaks. (3a) and (3b) show Doppler tracings with a late systolic notch, characterized by transient notching on the terminal aspect of the Doppler signal without 2 distinct peaks. Arrows indicate the location of the notch in the Doppler signal. Reprinted with permission of the American Thoracic Society. Copyright © 2019 American Thoracic Society. Arkles JS, Opatowsky AR, Ojeda J, et al. Shape of the right ventricular Doppler envelope predicts hemodynamics and right heart function in pulmonary hypertension. *Am J Respir Crit Care Med*. 2011;183(2):268–276. *The American Journal of Respiratory and Critical Care Medicine* is an official journal of the American Thoracic Society.

several noteworthy limitations. It is an invasive procedure with nontrivial risks to the patient, including complications related to bleeding, vascular, lung, or cardiac injury. In fact, a large prospective study across 54 centers in the United States, the REVEAL registry, observed that the average duration between symptom onset and diagnostic catheterization was 2.8 years in patients with World Health Organization (WHO) Group 1 PAH.<sup>4</sup> Further, common technical errors observed with RHC are often amplified in patients with underlying cardiopulmonary disease and, hence, several subgroups of PH. Wide variations across the respiratory cycle lead to underestimated end-expiratory values, and enlarged and dilated distal pulmonary artery branches in PVD make it difficult to obtain a fully occluded pulmonary capillary wedge pressure (PCWP), which can overestimate PCWP. RHC is often reserved only for patients in whom PVD is suspected, leaving a large population of PH patients where hemodynamic profiles are unknown and potentially misclassified. For this reason, novel approaches using echocardiography have emerged as a noninvasive and readily accessible alternative to hemodynamic assessment by catheterization.

Benza et al. performed a comprehensive evaluation of 2635 patients with PAH and observed that those who were initiated on therapy within 6 months of diagnosis had significantly improved

long-term survival.<sup>5</sup> Therefore, accurate identification of elevated PVR by echocardiography could reduce time to diagnosis of PVD and, more importantly, time to initiation of lifesaving PH therapies. Doppler echocardiography (DE)-derived estimates of PVR, such as the ratio of peak tricuspid regurgitation velocity to right ventricular outflow velocity-time integral (VTI<sub>RVOT</sub>) have shown excellent correlation with invasive PVR across several studies<sup>6,7</sup>; however, this correlation was not observed in patients with PVR > 8 WU.<sup>7</sup> Thus, patients with the most severe degree of PVD, and therefore the most clinically vulnerable and urgent, are excluded from accurate utility of this tool. Others have used DE to estimate variables included in the calculation of PVR such as pulmonary artery pressures and cardiac output; however, this approach is time intensive and less useful for clinical practice.<sup>8</sup> Arkles et al. demonstrated that easily observable differences in the shape of the right ventricular outflow tract (RVOT) Doppler signal could rapidly and accurately distinguish between patients with or without elevated PVR.<sup>9</sup> Specifically, the presence of “notching,” either midsystolic or late systolic notching, of the right ventricular (RV) Doppler envelope was strongly associated with a PVR > 3 WU (odds ratio = 29.4, 95% confidence interval [CI] = 9.9, 87.2<sup>9</sup>; Figure 1).

Similarly, Opatowsky et al. explored several models incorporating readily

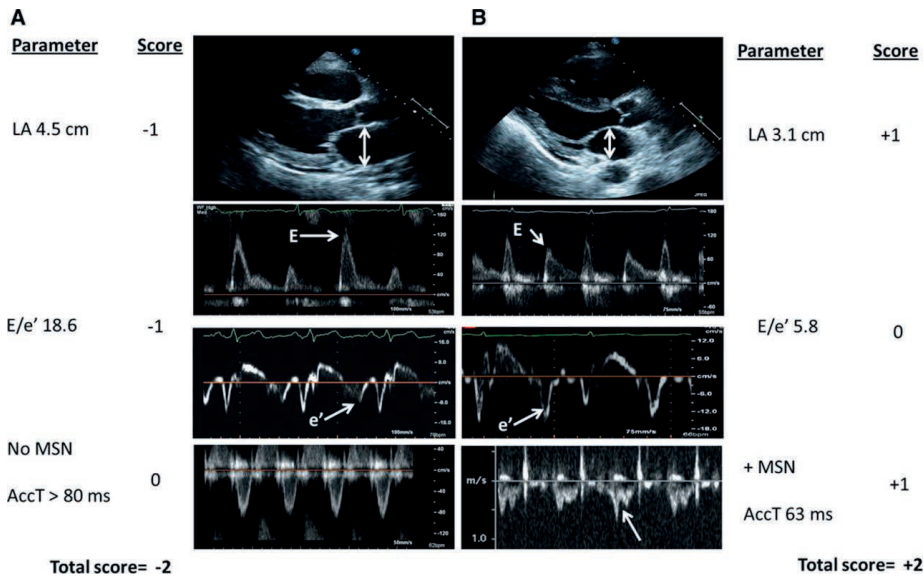
measurable echocardiographic parameters to estimate PVR.<sup>10</sup> The model (Equation 1) that correlated best with invasive PVR (correlation coefficient [ $r$ ] = 0.80) also exhibited excellent discriminatory power across a range of PVR values (area under curve [AUC] = 0.946 for PVR > 3 WU).

$$\text{PVR} = (\text{PASP} / \text{VTI}_{\text{RVOT}}) + 3 \text{ if notch present} \quad (1)$$

where PASP is pulmonary artery systolic pressure.

Further work done by Opatowsky et al. demonstrated that a simple prediction score based on a few easy-to-perform echocardiographic measurements (left atrial size, E/e' transmitral and tissue Doppler, and RVOT Doppler notch or acceleration time) had a positive likelihood ratio of 2.4 and a negative likelihood ratio of 0. A score >+2 was highly suggestive of PVD, whereas a negative score, in the presence of normal RV function (tricuspid annular plane systolic excursion or TAPSE > 1.8 cm), ruled out an elevated PVR<sup>11</sup> (Figure 2).

Some studies have suggested that there are measurable changes in the pulmonary vasculature that precede an elevation in PVR. Bhattacharya et al. defined pulmonary arterial compliance (PAC) as the ratio of VTI<sub>RVOT</sub> over PASP. In this particular study, 156 patients from the University of Penn-



**Figure 2:** Representative echocardiographic images of LA size, transmitral flow, tissue Doppler of the lateral mitral annulus, and RVOT Doppler showing score calculation for 2 patients. Column A (top to bottom) shows LA enlargement,  $\uparrow E/e'$ , and normal RVOT Doppler profile (score = -2). Invasive hemodynamics: mPAP = 40 mm Hg, PAWP = 29 mm Hg, PVR = 2.0 mm Hg/L/min. Column B demonstrates normal LA size, normal  $E/e'$ , and abnormal RVOT Doppler profile (score = +2). Invasive hemodynamics: mPAP = 45 mm Hg, PAWP = 10 mm Hg, PVR = 8.8 mm Hg/L/min. AccT = right ventricular outflow tract acceleration time; LA = left atrial; mPAP = mean pulmonary artery pressure; PAWP = pulmonary arterial wedge pressure; PVR = pulmonary vascular resistance; RVOT = right ventricular outflow tract. Reproduced with permission from Opatowsky AR, Ojeda J, Rogers F, et al. A simple echocardiographic prediction rule for hemodynamics in pulmonary hypertension. *Circ Cardiovasc Imaging*. 2012;5(6):765–775. See <https://www.ahajournals.org/journal/circimaging>. Published by the American Heart Association.

sylvania were included only if they had a preserved ejection fraction (HFpEF). By including patients without reduced LVEF, the investigators of the study were able to demonstrate that PAC, measured by  $VTI_{RVOT}/PASP$ , can readily distinguish between PAH and PH due to HFpEF. Compared to other previously published measures of PAC, the use of  $VTI_{RVOT}$  as a surrogate for RV stroke volume is more sensitive because it incorporates both basal and free wall motion (compared to TAPSE, for example). Finally, to further support the clinical relevance of this the authors of this study showed that, after multivariate adjustment,  $VTI_{RVOT}/PASP$  remained an independent predictor of 6-minute walk distance, a known prognostic marker in PH. While there is certainly promise in the use of PAC as a marker of early disease, further investigation is needed to determine whether PAC correlates with change in hemodynamics and functional capacity after initiation of PH medications and thus

serves as a clinical marker of treatment responsiveness.<sup>12</sup>

## ASSESSMENT OF THE RIGHT HEART

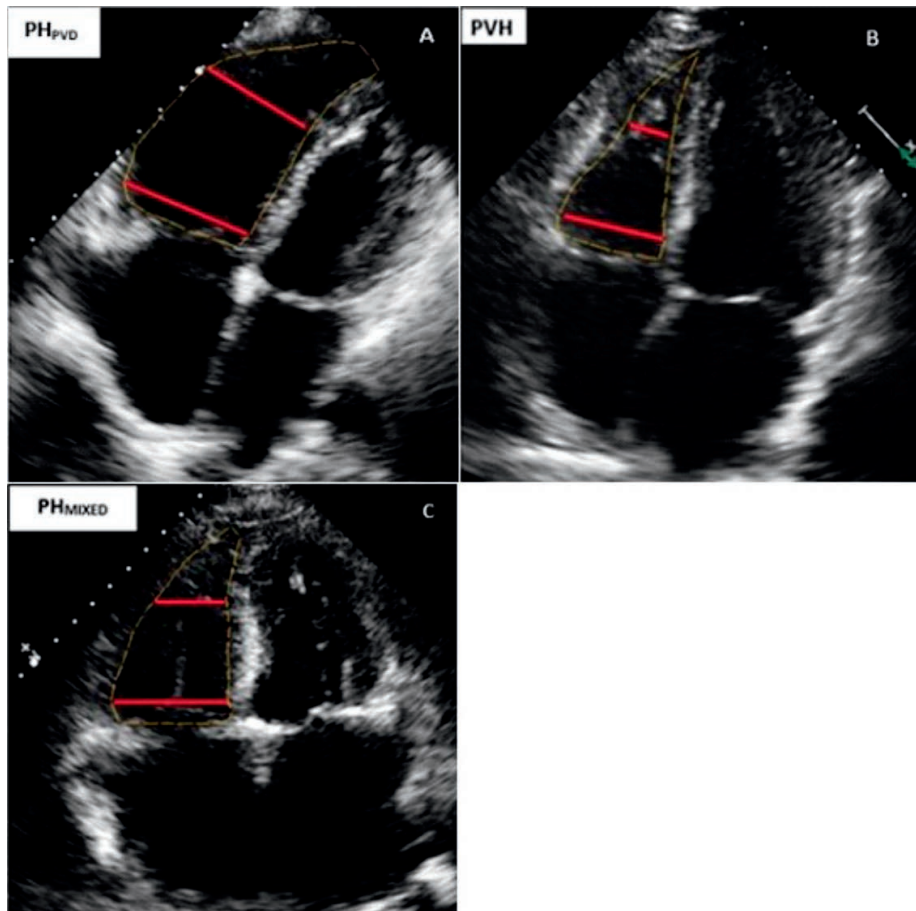
### RV Morphology

Because there are many factors that contribute to RV function (right heart preload, afterload, intrinsic contractile function, and right atrial function), it is not surprising that echocardiographic parameters of RV function lack specificity to discriminate among different clinical forms of PH. Raza et al. explored whether there are specific profiles of RV shape or morphology that can be used to identify and distinguish among 3 PH subtypes: PVD; pulmonary venous hypertension, or PVH (such as PH due to left heart disease); and those with a mixed phenotype (PVD and PVH). The authors of this study showed the RV base and apex dimensions were nearly the same in the PVD group, while the RV apex dimension was approximately half of that of the base in patients with

PVH (Figure 3). Specifically, RV base and apex of similar dimensions ( $sRV_{b/a} < 1.5$ ) were associated with a 17 times increased odds of having a PVR > 3 WU.  $sRV_{b/a}$  (AUC = 0.873) outperformed parameters which measure RV function, namely TAPSE (AUC = 0.563) and fractional area change (AUC = 0.700), suggesting that the RV undergoes morphological changes prior to a reduction in function. Finally, a low  $sRV_{b/a}$  and presence of dilated left atrium (>40 mm) correctly identified patients with mixed-physiology PH with a mean PVR of  $8.4 \pm 4.5$  WU and mean PCWP of  $18.0 \pm 5.4$  mmHg.<sup>13</sup>

### RV Function

**TAPSE:** The presence of RV dysfunction has been widely recognized as an independent predictor of poor outcomes in PH. In a study of 110 patients with PAH, 25% of patients who experienced an improvement in PVR after medical therapy continued to have worsening RV function and ultimately had the worst outcomes, suggesting that RV dysfunction may be specific for severe or refractory disease.<sup>14</sup> Similar to RHC, cardiac magnetic resonance imaging, which is the “gold standard” imaging modality to assess RV function, is limited by cost, accessibility, and patient-related factors such as claustrophobia and inability to lay supine. In normal right hearts, longitudinal shortening accounts for up to 80% of overall RV function.<sup>15</sup> For this reason, systolic displacement of the tricuspid annulus toward the RV apex or TAPSE is frequently investigated as an echocardiographic surrogate of RV function. Compared to other echocardiographic measurements of RV function, TAPSE offers several advantages in that it is highly reproducible, independent of geometric assumptions, and does not require RV endocardial tracing which is prone to error and technical difficulty.<sup>16</sup> In a prospective study of a heterogeneous population of PH, with approximately 75% in WHO Group 1, TAPSE < 1.8 cm was associated with a fourfold increased risk of death.<sup>17</sup> Follow-up TAPSE measurements, and not baseline, after initiation of PAH therapy predicted survival in a cohort of PAH patients. Specifically, follow-up TAPSE



**Figure 3:** Representative echocardiographic apical 4-chamber view of 3 different groups of pulmonary hypertension (PH). (A) PH<sub>PVD</sub> = pulmonary vascular disease, (B) PVH = pulmonary venous hypertension, (C) PH<sub>MIXED</sub> = PH mixed physiology. Endocardium is marked with orange-colored broken line, red lines mark RV basal diameter (above tricuspid annulus) and RV apical diameter (level of moderator band). RV = right ventricle; LV = left ventricle; RA = right atrium; LA = left atrium. Reproduced from Raza F, Dillane C, Mirza A, et al. Differences in right ventricular morphology, not function, indicate the nature of increased afterload in pulmonary hypertensive subjects with normal left ventricular function. *Echocardiography*. 2017;34(11):1584–1592, with permission from John Wiley & Sons, Inc.

≥ 2 cm was associated with a decrease in all-cause mortality (hazard ratio = 0.21, 95% CI = 0.08, 0.60) and improved WHO functional class and 6-minute walk distance.<sup>18</sup>

Prior to a study published by Sivak et al., it was unclear how much right atrial function contributed to RV function. Because total RV function is largely due to longitudinal shortening, Sivak et al. hypothesized that the increased distance between RV base and apex that occurs during right atrial systole is an important contributor to overall RV function. They compared 37 patients with PAH to 35 healthy controls and showed that RA systolic function accounted for 51% of TAPSE compared to only 32% in controls.<sup>19</sup> This has important clinical

implications in that maintenance of sinus rhythm in PAH is essential for preserving RV function.

Several studies have highlighted the significance of nonlongitudinal shortening of the RV, particularly in the context of underlying cardiopulmonary disease. It was initially observed that TAPSE values were lower in cardiac surgery patients, but overall RV function appeared to be preserved. This led to a study by Vaidya et al., who compared RV contractile patterns in patients who underwent cardiac surgery with controls. They found that, in the surgical cohort, there was a dramatic decrease in longitudinal shortening, but overall RV function was normal due to a gain in transverse shortening.<sup>20</sup> In this patient

population, a lower value of TAPSE could be misleading; therefore, careful examination for special cases of RV contractile patterns, such as postcardiothoracic surgery patients, should be part of routine RV functional assessment.

**Limitations of PASP Estimation:** In a single-center prospective analysis of PH patients who underwent RHC and had DE performed 1 hour later, pulmonary artery pressures derived from DE differed significantly from those measured invasively (48% > ±10 mm Hg of the invasive measurement). In the case of underestimated measurements, the Doppler jet across the tricuspid valve was of poor quality, a significant limitation in DE. Approximately half of the cases that had overestimated PASP had overestimated right atrial pressures. Therefore, known physiologic variations in inferior vena cava collapsibility can cause variability in right atrial pressures and is also a source of error in PASP estimation. In patients with underlying lung disease, it is technically more difficult to obtain optimal window views of the tricuspid regurgitant jet, which leads to inaccurate estimation of PASP.<sup>21</sup>

## CONCLUSIONS

- Echocardiography allows clinicians to simultaneously investigate the interplay between pathologic remodeling of the pulmonary vasculature in PH and the right heart's adaption to it, thus providing a powerful means for comprehensive assessment.
- Novel echocardiographic measures and scoring tools can enable clinicians to confidently predict a patient's predominant hemodynamic profile across several subtypes and severity of PH.
- Careful echocardiography interpretation should be used in conjunction with RHC, including serially, in the context of disease progression and response to therapy.

## References

1. Hatano S, Strasser TE, eds. *Primary Pulmonary Hypertension: Report on a WHO Meeting*.



- Geneva, Switzerland: World Health Organization; 1975.
2. Kovacs G, Berghold A, Scheidl S, Olschewski H. Pulmonary arterial pressure during rest and exercise in healthy subjects: a systematic review. *Eur Respir J*. 2009;34(4):888–894. doi:10.1183/09031936.00145608.
  3. Simonneau G, Montani D, Celermajer DS, et al. Haemodynamic definitions and updated clinical classification of pulmonary hypertension. *Eur Respir J*. 2019;53(1). doi:10.1183/13993003.01913-2018.
  4. Badesch DB, Raskob GE, Elliott CG, et al. Pulmonary arterial hypertension: baseline characteristics from the REVEAL registry. *Chest*. 2010;137(2):376–387. doi:10.1378/chest.09-1140.
  5. Benza RL, Miller DP, Barst RJ, Badesch DB, Frost AE, McGoon MD. An evaluation of long-term survival from time of diagnosis in pulmonary arterial hypertension from the REVEAL registry. *Chest*. 2012;142(2):448–456. doi:10.1378/chest.11-1460.
  6. Abbas AE, Fortuin FD, Schiller NB, Appleton CP, Moreno CA, Lester SJ. A simple method for noninvasive estimation of pulmonary vascular resistance. *J Am Coll Cardiol*. 2003;41(6):1021–1027. doi:10.1016/S0735-1097(02)02973-X.
  7. Rajagopalan N, Simon MA, Suffoletto MS, et al. Noninvasive estimation of pulmonary vascular resistance in pulmonary hypertension. *Echocardiography*. 2009;26(5):489–494. doi:10.1111/j.1540-8175.2008.00837.x.
  8. Selimovic N, Rundqvist B, Bergh CH, et al. Assessment of pulmonary vascular resistance by Doppler echocardiography in patients with pulmonary arterial hypertension. *J Heart Lung Transplant*. 2007;26(9):927–934. doi:10.1016/j.healun.2007.06.008.
  9. Arkles JS, Opatowsky AR, Ojeda J, et al. Shape of the right ventricular Doppler envelope predicts hemodynamics and right heart function in pulmonary hypertension. *Am J Respir Crit Care Med*. 2011;183(2):268–276. doi:10.1164/rccm.201004-0601OC.
  10. Opatowsky AR, Clair M, Afilalo J, et al. A simple echocardiographic method to estimate pulmonary vascular resistance. *Am J Cardiol*. 2013;112(6):873–882. doi:10.1016/j.amjcard.2013.05.016.
  11. Opatowsky AR, Ojeda J, Rogers F, et al. A simple echocardiographic prediction rule for hemodynamics in pulmonary hypertension. *Circ Cardiovasc Imaging*. 2012;5(6):765–775. doi:10.1161/CIRCIMAGING.112.976654.
  12. Bhattacharya PT, Troutman GS, Mao F, et al. Right ventricular outflow tract velocity time integral-to-pulmonary artery systolic pressure ratio: a non-invasive metric of pulmonary arterial compliance differs across the spectrum of pulmonary hypertension. *Pulm Circ*. 2019;9(2):1–10. doi:10.1177/2045894019841978.
  13. Raza F, Dillane C, Mirza A, et al. Differences in right ventricular morphology, not function, indicate the nature of increased afterload in pulmonary hypertensive subjects with normal left ventricular function. *Echocardiography*. 2017;34(11):1584–1592. doi:10.1111/echo.13699.
  14. van de Veerdonk MC, Kind T, Marcus JT, et al. Progressive right ventricular dysfunction in patients with pulmonary arterial hypertension responding to therapy. *J Am Coll Cardiol*. 2011;58(24):2511–2519. doi:10.1016/j.jacc.2011.06.068.
  15. Brown SB, Raina A, Katz D, Szerlip M, Wiegers SE, Forfia PR. Longitudinal shortening accounts for the majority of right ventricular contraction and improves after pulmonary vasodilator therapy in normal subjects and patients with pulmonary arterial hypertension. *Chest*. 2011;140(1):27–33. doi:10.1378/chest.10-1136.
  16. Sanjiv K, Tei C, Hopkins JM, Shah PM. Assessment of right ventricular function using two-dimensional echocardiography. *Am Heart J*. 1984;107(3):526–531. doi:10.1177/108925329700100304.
  17. Forfia PR, Fisher MR, Mathai SC, et al. Tricuspid annular displacement predicts survival in pulmonary hypertension. *Am J Respir Crit Care Med*. 2006;174(9):1034–1041. doi:10.1164/rccm.200604-547OC.
  18. Mazurek JA, Vaidya A, Mathai SC, Roberts JD, Forfia PR. Follow-up tricuspid annular plane systolic excursion predicts survival in pulmonary arterial hypertension. *Pulm Circ*. 2017;7(2):361–371. doi:10.1177/2045893217694175.
  19. Sivak J, Raina A, Forfia P. Assessment of the physiologic contribution of right atrial function to total right heart function in patients with and without pulmonary arterial hypertension. *Pulm Circ*. 2016;6(3):322–328. doi:10.1086/687767.
  20. Raina A, Vaidya A, Gertz ZM, Chambers S, Forfia PR. Marked changes in right ventricular contractile pattern after cardiothoracic surgery: implications for post-surgical assessment of right ventricular function. *J Heart Lung Transplant*. 2013;32(8):777–783. doi:10.1016/j.healun.2013.05.004.
  21. Fisher MR, Forfia PR, Chamera E, et al. Accuracy of Doppler echocardiography in the hemodynamic assessment of pulmonary hypertension. *Am J Respir Crit Care Med*. 2009;179(7):615–621. doi:10.1164/rccm.200811-1691OC.

# Multimodality Imaging of Pulmonary Hypertension

Seth Kligerman, MD  
Department of Radiology  
Cardiothoracic Imaging Section  
University of California San Diego School  
of Medicine  
La Jolla, CA

Michael Horowitz, MD, PhD  
Department of Radiology  
University of California San Diego School  
of Medicine  
La Jolla, CA

Albert Hsiao, MD, PhD  
Department of Radiology  
University of California San Diego School  
of Medicine  
La Jolla, CA

Lewis Hahn, MD  
Department of Radiology  
University of California San Diego School  
of Medicine  
La Jolla, CA

Elizabeth Weihe, MD  
Department of Radiology  
University of California San Diego School  
of Medicine  
La Jolla, CA

## PULMONARY HYPERTENSION

Elevated pulmonary arterial pressures are the result of a spectrum of diseases that have been classified into 5 categories by the World Symposium on Pulmonary Hypertension.<sup>1</sup> The finding of pulmonary hypertension (PH) is usually the first step in a multidisciplinary workup to diagnose the underlying cause, as different etiologies have different treatment algorithms and outcomes. Diagnostic imaging plays a key role in not only the initial evaluation of a patient with PH, but also to assess disease progression or treatment response.

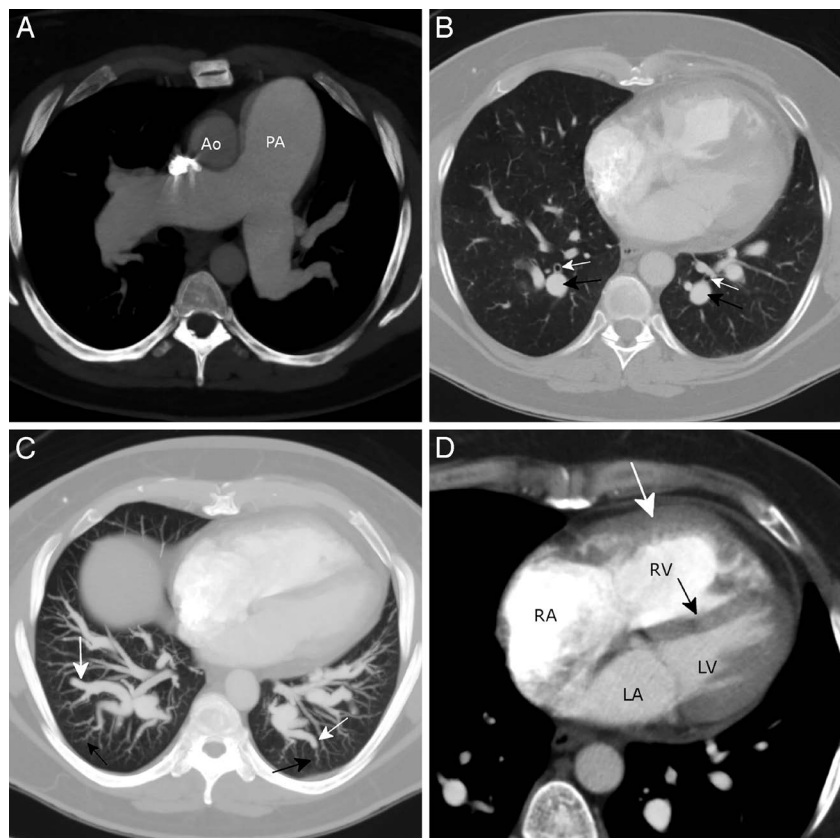
In trying to discover the underlying cause of PH, the diagnostic radiologist often must act as a detective. While some findings, such as varying degrees of enlargement of the pulmonary trunk and remodeling of the right heart, are ubiquitous in patients with PH, it is often the more subtle findings that can help elucidate the cause. These findings may be isolated to the lung parenchyma or may involve the pulmonary or systemic vasculature, heart, or mediastinum. The purpose of this article is to review the various findings of PH on computed tomography (CT) and ventilation/perfusion (V/Q) scans that can help one to differentiate between the various etiologies.

## ASSESS THE PULMONARY VASCULATURE

When evaluating the pulmonary vasculature, there are various findings suggestive

of PH that are common between the various causes. These include pulmonary artery (PA) enlargement, PA-to-aorta

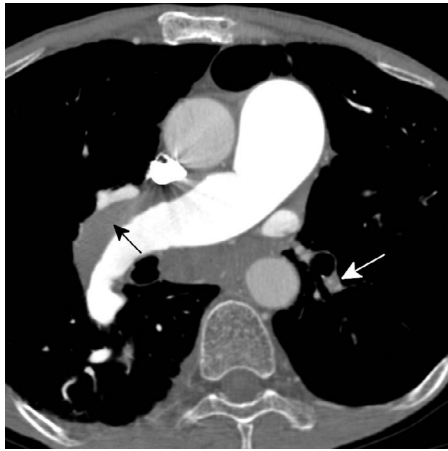ratio >1, and an increased segmental artery-to-bronchus ratio (Figure 1).<sup>2</sup> While 3 cm is often used as a normal



**Figure 1:** Idiopathic pulmonary arterial hypertension (PAH) in a 35-year-old woman. (A) Axial maximum intensity projection (MIP) image shows a dramatically enlarged pulmonary artery (PA) measuring 4.6 cm. This is much larger in size than the adjacent ascending aorta (Ao). (B) Examination of the segmental PAs (black arrows) show that they are much larger in diameter compared to the adjacent segmental bronchi (white arrows) consistent with pulmonary hypertension (PH). (C) Axial MIP through the lower lobes shows relatively rapid tapering of the PAs as they extend toward the periphery of the lung (white arrows). Some of the vessels have a corkscrew appearance common in cases of severe PH (black arrows). (D) Axial image through the heart shows pronounced thickening of the right ventricular (RV) wall (white arrow) due to RV hypertrophy. There is flattening of the interventricular septum (black arrow) toward the left ventricle (LV) due to increased RV pressures. The right atrium (RA) is also larger than the left atrium (LA) due to PH.

Correspondence: skligerman@ucsd.edu

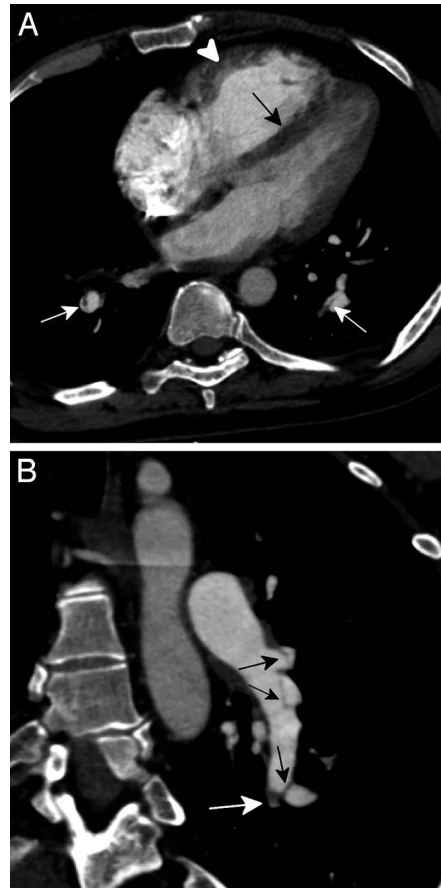
Disclosure: The authors have no relevant personal financial relationships to disclose.



**Figure 2:** Axial image through the main pulmonary artery (PA) in 60-year-old man with chronic thromboembolic pulmonary hypertension shows narrowing and occlusion of the left lower lobe PA (white arrow). There is layering chronic thrombus in the right main PA (black arrow).

cutoff value for PA size, it is by no means a diagnostic finding as studies have found no direct correlation between PA diameter and mean PA pressure.<sup>3</sup> Multiple factors can affect PA size and include body mass index, systemic hypertension, diabetes, age, and underlying cardiovascular disease.<sup>4</sup> Therefore, if the main PA measures  $>3$  cm, one should also look at size of the segmental arteries and adjacent bronchi. While a segmental PA-to-bronchi ratio greater than 1:1 is weakly correlated with elevated PA pressures,<sup>5</sup> the presence of both parameters has a high specificity for the diagnosis of PH.<sup>3</sup> An alternative and often preferred method is to assess the diameters of the main PA and the aorta. A ratio  $>1$  is commonly associated with PH.<sup>5,6</sup>

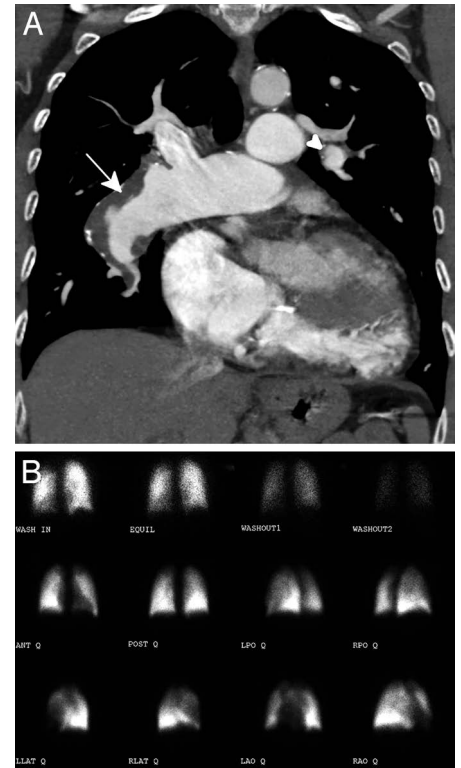It is extremely important to recognize chronic thromboembolic PH (CTEPH) as a cause of PH since invasive treatments can be curative.<sup>7</sup> While disease involving the central vasculature can be quite conspicuous (Figure 2), with large chronic clots layering in and sometimes obliterating the lumen of the main and lobar arteries, disease isolated to the peripheral vasculature can be quite subtle. Close inspection of the segmental and subsegmental pulmonary vasculature on pulmonary angiography CT scans can show abrupt occlusion of PAs with a “pouch” defect, luminal irregularities with eccentric wall thickening, abrupt



**Figure 3:** 45-year-old woman with chronic thromboembolic pulmonary hypertension. (A) 4-chamber reconstruction shows flattening of the interventricular septum (black arrow) due to elevated right heart pressures and right ventricular hypertrophy (white arrow). Nonocclusive webs are seen in the posterior segmental arteries in the lower lobes (white arrows). (B) Coronal oblique reconstruction through the right lower lobe pulmonary artery shows proximal segmental webs (black arrows). In addition, there is occlusion of the posterior segment (white arrow) with a pouchlike appearance.

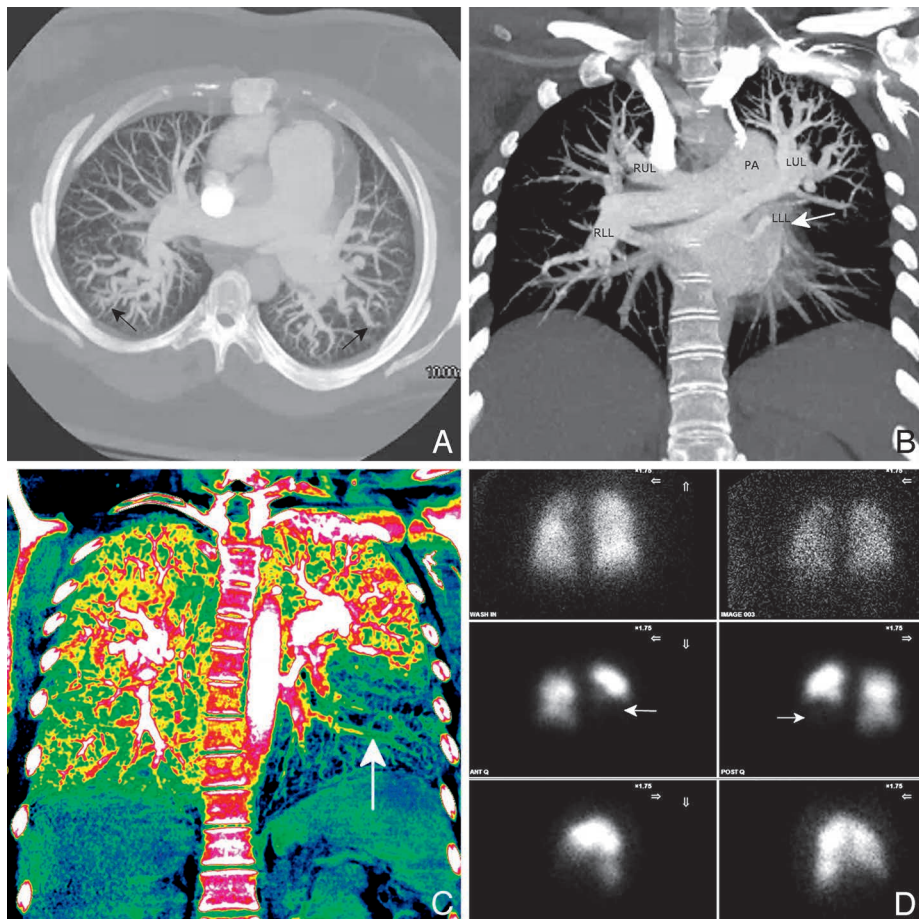
caliber change (often due to recanalization), and webs or bands (Figure 3).<sup>8–10</sup>

Pulmonary arterial hypertension (PAH, Group 1) includes idiopathic PAH, heritable PAH, drug/toxin-induced PAH, and PAH associated with connective tissue disease, human immunodeficiency virus (HIV) infection, portal hypertension, congenital heart disease, and schistosomiasis.<sup>1</sup> In severe longstanding PAH, in situ thrombus and calcified atherosclerosis along the walls of the PAs may develop due to extremely high pressures (Figure 4). Even among experts, these findings can



**Figure 4:** In situ thrombus in a 34-year-old woman with pulmonary arterial hypertension (PAH). (A) Coronal computed tomography scan shows calcified and noncalcified layering thrombus in the right main pulmonary artery (white arrow). Extensive layering thrombus was also present on the left, a portion of which is seen in a segmental left upper lobe artery (white arrowhead). (B) Ventilation/perfusion scan in this patient shows heterogeneous perfusion throughout the lungs common in PAH. However, there are no mismatched defects to suggest chronic thromboembolic pulmonary hypertension.

be mistaken for CTEPH, and given the differences in treatment, this distinction is quite important. One method to distinguish is to evaluate the morphology of the more peripheral vessels. While both can give rise to “corkscrew” appearing vessels and/or peripheral pruning of the vasculature, in PAH the findings are diffuse (Figure 1), while in CTEPH there are often discrete areas of lobar, segmental, and subsegmental obliteration (Figure 2). V/Q scan or dual-energy CT angiography can often help differentiate. In PAH, one will see heterogeneous regional perfusion without mismatch on V/Q scan or occlusive filling defects on CT scan (Figure 4). In CTEPH, V/Q mismatches correspond to vascular territories, and



**Figure 5:** Chronic thromboembolic pulmonary hypertension in a 45-year-old woman. (A) Axial maximum intensity projection (MIP) image shows an enlarged pulmonary artery (PA) and multiple corkscrew-shaped vessels due to pulmonary hypertension (PH). (B) Coronal MIP shows complete occlusion of the left lower lobe PA due to chronic thrombus (white arrow). There is no associated arterial perfusion to the left lower lobe (LLL). The visualized vessels in the LLL represent pulmonary veins. Due to this occlusion, there is compensatory engorgement of the PAs in the left upper lobe (LUL) when compared to the relatively normal branches in the right upper lobe (RUL) and right lower lobe (RLL). The main PA is enlarged. (C) Associated coronal image from a dual-energy computed tomography scan shows lack of perfusion to the LLL (white arrow) corresponding to findings on (D) ventilation/perfusion scan (white arrows).

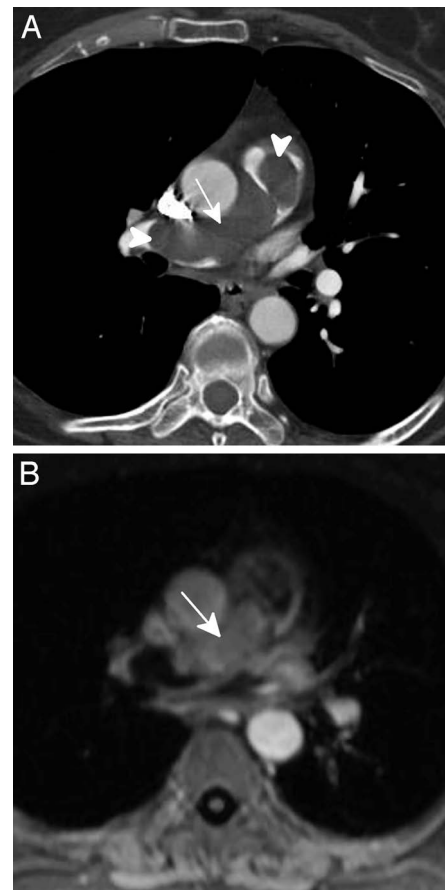
discrete occlusive lobar, segmental, and subsegmental filling defects can often be seen on CT (Figure 5). Another method of differentiation is the evaluation of the pulmonary parenchyma, as discussed below, which show distinct changes associated with the underlying pathophysiology.

Another less common mimic of CTEPH is a PA sarcoma. Differentiation between these two entities can be difficult, which is highlighted by the fact that most PA sarcomas are initially misinterpreted as intravascular thrombus.<sup>11,12</sup> However, certain findings, if present, are suggestive of a sarcoma, including a soft tissue mass nearly filling and potentially expanding the lumen of

the pulmonary trunk, left PA, or right PA with protrusion of the proximal end of this mass towards the right ventricular (RV) outflow tract (Figure 6).<sup>11</sup> The ends of the soft tissue mass are often curvilinear. The mass can demonstrate enhancement on portal-venous phase of imaging. Positron emission tomography-CT and magnetic resonance imaging may need to be performed to differentiate in complex cases.

### EVALUATE THE HEART AND SYSTEMIC VASCULATURE

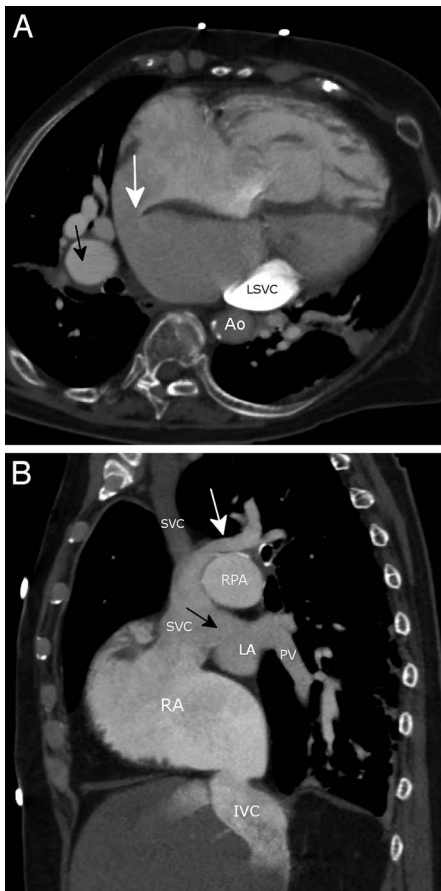
In addition to remodeling the PAs, chronically elevated pulmonary pressures cause remodeling of the right heart. Findings such as RV hypertrophy (free



**Figure 6:** Pulmonary artery (PA) sarcoma in a 68-year-old man. (A) Axial computed tomography scan shows a large mass filling the right PA (white arrow) and extending proximally toward the right ventricular outflow track (white arrowhead). The edges of the mass are curvilinear which is common with PA sarcomas. The patient was initially treated with anticoagulation without effect. (B) Axial magnetic resonance image through the same level shows intense enhancement in the center of the mass (white arrow) consistent with a sarcoma. A thrombus would not be expected to enhance.

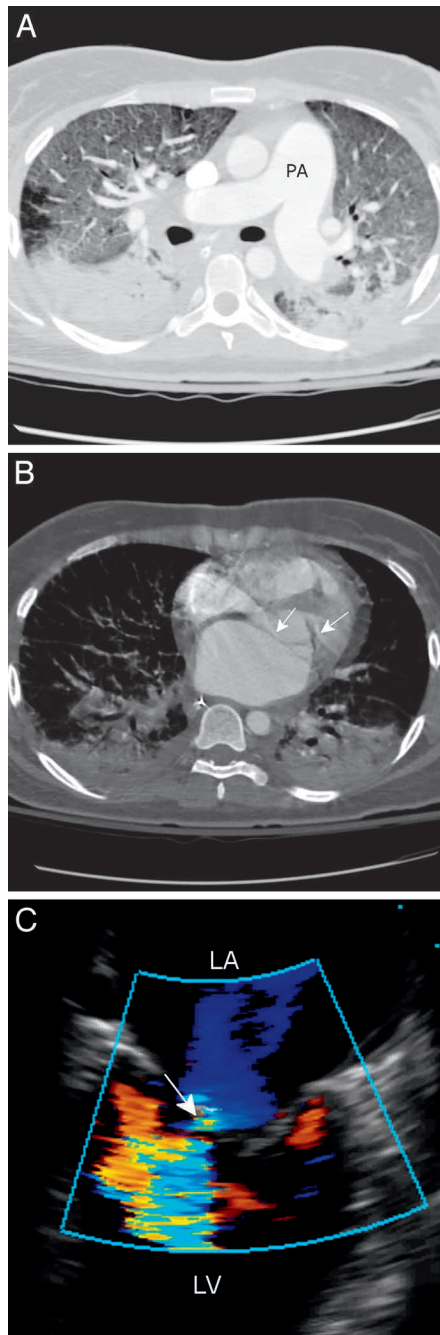
wall thickness >4 mm), RV dilatation (>1:1 ratio between RV and left ventricle diameter on axial images), and flattening or leftward deviation of the interventricular septum<sup>13</sup> are associated with increased pulmonary pressures (Figures 1 and 2). PH can lead to RV failure, which is often associated with dilation of the inferior vena cava with reflux of contrast into the hepatic veins (Figure 7). Prolonged hepatic congestion can lead to cirrhosis.<sup>14</sup>

The presence of a dilated right heart (with or without hypertrophy) should always prompt a careful search for an undiagnosed intracardiac or extracardiac



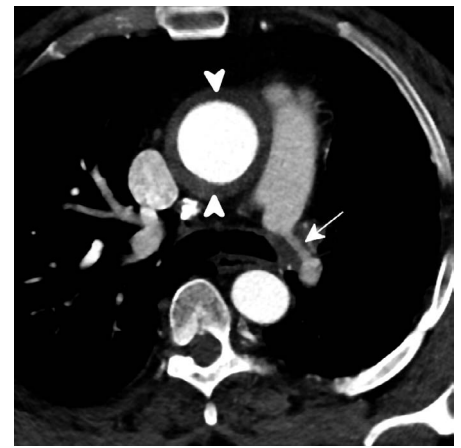
**Figure 7:** 67-year-old woman presenting to the emergency department with shortness of breath. **(A)** 4-chamber image through the heart from a pulmonary embolism computed tomography angiography shows a dilated right heart and right lobe pulmonary artery (black arrow) consistent with pulmonary hypertension. A defect is present in the superolateral and posterior aspect of the interventricular septum consistent with a sinus venosus atrial septal defect (SV-ASD). Incidental note is made of a left-sided superior vena cava (LSVC). **(B)** Sagittal oblique image through the heart shows a dilated right atrium (RA) and reflux of contrast into a distended inferior vena cava (IVC) due to elevated right heart pressures. The right-sided superior vena cava (SVC) is mildly enlarged centrally. An SV-ASD (black arrow) is present along the inferior aspect of the SVC near its junction with the RA allowing for communication between the right heart and the left atrium (LA). The right inferior pulmonary vein (PV) drains into the LA. The right superior pulmonary vein (white arrows) anomalously drains into the SVC (white arrow) consistent with a partial anomalous pulmonary venous return. The 2 anomalies coexist in the majority of cases of a SV-ASD.

shunt as the cause of PH (Figure 7). Evaluation of the cardiac valves, even on a study performed without cardiac electrocardiogram gating, should



**Figure 8:** Longstanding mitral stenosis (MS) leading to pulmonary hypertension in a 70-year-old woman. **(A)** Axial computed tomography image shows a dilated main pulmonary artery (PA). There is diffuse ground glass opacity with septal thickening due to pulmonary edema. **(B)** Axial image through the heart shows a dilated left atrium with thickening of the mitral valve leaflets (white arrows). **(C)** Doppler image from an echocardiogram shows a high velocity jet flowing from the left atrium (LA) into the left ventricle (LV) through a severely stenotic mitral valve with a markedly reduced opening area (white arrow).

be performed. Mitral stenosis, which manifests as thickening and calcification of the valve leaflets with severe left atrial dilation, can lead to PH (Figure 8). The



**Figure 9:** Axial computed tomography in a 20-year-old woman with Takayasu's arteritis shows marked narrowing of the left pulmonary artery (white arrow) due to vasculitis. The right pulmonary artery was also narrowed. Circumferential thickening of the wall of the aorta (white arrowheads) helps make the diagnosis of a large vessel vasculitis.

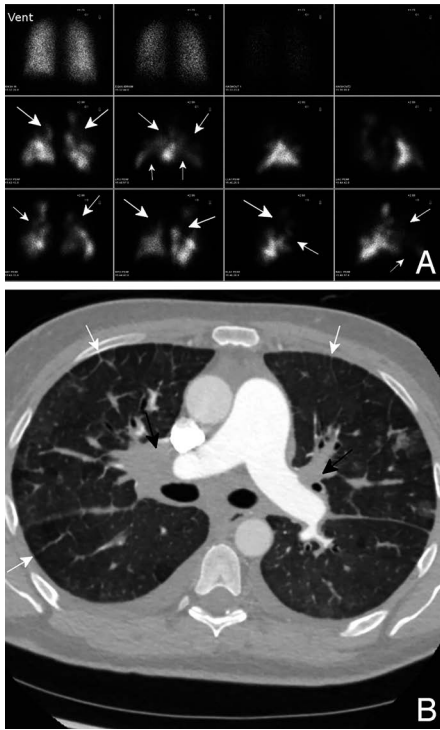
aorta and branch vessels should also be assessed for irregularities, such as areas of stenosis and aneurysmal dilation, that may signify an underlying vasculitis as the cause of the PH (Figure 9).

## ASSESS THE PARENCHYMA

### *Interlobular Septal Thickening*

Interlobular septal thickening is most often seen in PH due to left heart failure. Smooth septal thickening represents the increased interstitial congestion/edema of the pulmonary veins and lymphatics related to increased left atrial pressures (Figure 8). Ultimately, the passive backward transmission of increased left atrial filling pressures leads to the pulmonary vascular remodeling and right heart failure associated with PH. Irregular septal thickening can be seen along with reticulation with fibrosis, and nodular septal thickening can be seen with sarcoidosis and lymphangitic disease.<sup>15</sup>

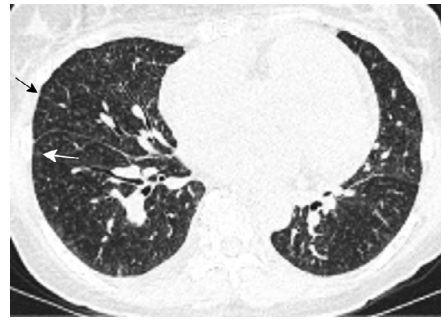
In the absence of left heart failure/enlargement, interlobular septal thickening associated with PAH is the hallmark of postcapillary congestion seen in patients with pulmonary veno-occlusive disease (PVOD). PVOD is characterized by intimal fibrosis, which leads to the occlusion and narrowing of pulmonary veins from the postcapillary level and beyond. As a consequence, the lymphatic channels within the interlobular septa dilate and become edematous, leading to the



**Figure 10:** Pulmonary veno-occlusive disease (PVOD) in a 34-year-old woman. (A) Ventilation/perfusion scan shows multiple areas of mismatch leading to a high-probability diagnosis of pulmonary emboli. (B) Subsequent computed tomography pulmonary angiography shows an enlarged main pulmonary artery but no acute or chronic pulmonary emboli. However, there is diffuse septal thickening (white arrows), bilateral enlarged hilar lymph nodes (black arrows), and a few scattered areas of ground glass opacity. The findings were highly suggestive of PVOD, which was confirmed on biopsy.

smooth interlobular septal thickening classically seen on CT (Figure 10) and the septal thickening (Kerley B lines) seen on radiographs.<sup>16,17</sup> In PVOD, smooth interlobular septal thickening is often associated with scattered ground glass opacities, pleural effusions, and mediastinal lymphadenopathy.<sup>16–18</sup> V/Q scans are regarded as nonspecific for PVOD and can have a wide range of interpretations ranging from normal to findings of “high probability” with mismatched perfusion defects.<sup>16,19</sup>

PVOD can be classified as idiopathic or associated to other conditions, including systemic sclerosis, HIV infection, pulmonary Langerhans histiocytosis, and sarcoidosis. PVOD is likely underestimated in sarcoid-associated PH (SAPH) and radiographically seen as smooth interlobular septal thickening with associated patchy areas of ground



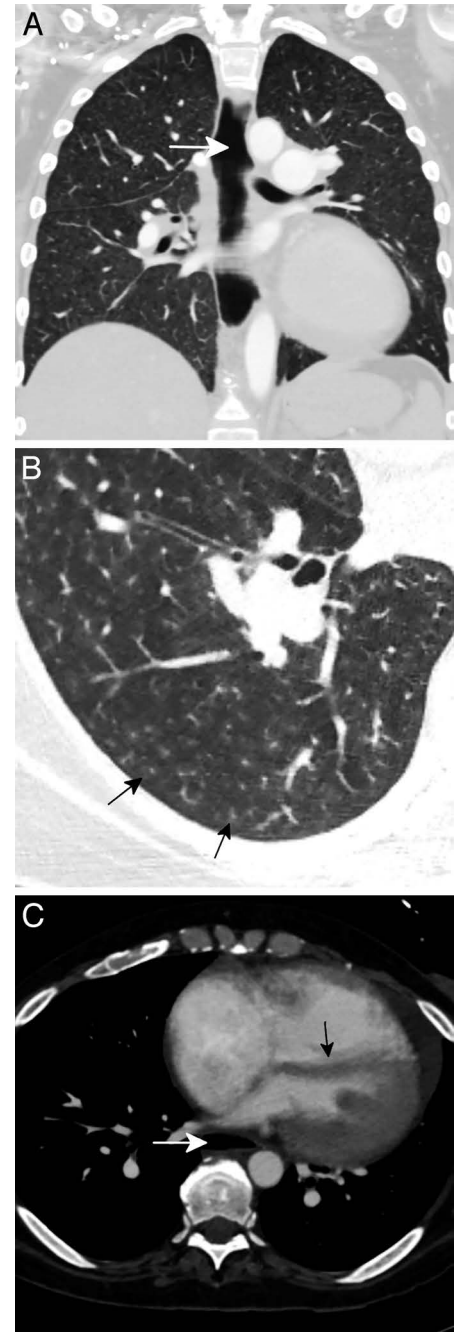
**Figure 11:** Axial computed tomography image in a 59-year-old woman with dyspnea demonstrates diffuse centrilobular nodularity (white arrow) due to pulmonary capillary hemangiomatosis (PCH). Associated septal thickening is seen but to a lesser extent than in most cases of pulmonary veno-occlusive disease (PVOD). Given that PCH/PVOD share similar hemodynamic, clinical, and radiographic findings, revised guidelines recommend that PVOD and PCH be combined into a single diagnosis called “PAH with overt features of venous/capillaries (PVOD/PCH) involvement.”

glass and/or venous infarcts.<sup>20</sup> The pathophysiology of SAPH is complex and often multifactorial with 40% to 60% of patients with SAPH having no radiographic evidence of fibrosis.<sup>20</sup>

#### Nodules

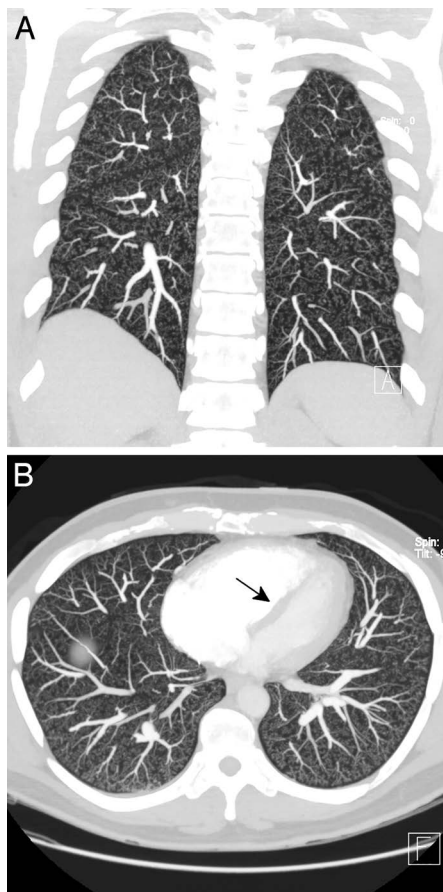
In an untreated patient with PAH, the presence of hazy centrilobular nodularity should raise the possibility for pulmonary capillary hemangiomatosis (PCH; Figure 11). These nodules are often diffuse in nature, involve all lobes, and spare the lung periphery.<sup>16,21</sup> Although the distinction between PCH and PVOD on imaging can be difficult, septal thickening and pleural effusions are less common in PCH.<sup>21</sup> In PCH, they represent the capillary proliferation within the alveolar walls; however, in PVOD these nodules represent the looplike capillary engorgement seen secondary to pulmonary venous narrowing and stenosis.<sup>16</sup> Given that PCH/PVOD share similar hemodynamic, clinical, and radiographic findings, revised guidelines recommend that PAH with PVOD/PCH belong to a subgroup of Group 1 PH (subgroup 1.6) for the spectrum of pulmonary vascular disease known as “PAH with overt features of venous/capillaries (PVOD/PCH) involvement,” as opposed to two distinct entities.<sup>22</sup>

In patients with PAH not related to PVOD/PCH, hazy ground glass centri-



**Figure 12:** Pulmonary arterial hypertension with ground glass nodules in a 52-year-old woman with scleroderma. (A) Coronal image shows a diffusely dilated esophagus (white arrow). (B) Innumerable small ground glass centrilobular nodules are present, which are better seen on a coned down image through the right lower lobe (black arrows). (C) Axial image through the heart shows marked dilated and hypertrophy of the right ventricle with flattening of the interventricular septum (black arrow). The dilated esophagus (white arrow) helps suggest the diagnosis of scleroderma.

lobular nodules can occur and can mimic findings seen in PCH (Figure 12).<sup>23</sup> While the nodules in PCH represent



**Figure 13:** Excipient lung disease in a 25-year-old man who injected crushed OxyContin tablets. **(A)** Coronal maximum intensity projection (MIP) image shows innumerable well-defined centrilobular nodules throughout the entire lung. There is conspicuous sparing of the fissures due to the centrilobular distribution. These nodules are due to microemboli of excipient fragments into the pulmonary arterioles leading to a granulomatous reaction. Unlike the centrilobular nodules seen in pulmonary arterial hypertension, these tend to be more well defined. **(B)** Axial MIP through the heart shows marked dilated and hypertrophy of the right ventricle with flattening of the interventricular septum (black arrow). Innumerable well-defined centrilobular nodules are again seen.

capillary proliferation in the alveolar walls, this finding in PAH has been attributed to periarteriolar cholesterol granulomas, large plexogenic arterial lesions, or small systemic collateral arteries.<sup>24,25</sup> Distinction between the two can be difficult and may require biopsy. However, hazy centrilobular ground glass nodules are uncommon in other causes of PH.<sup>13</sup>

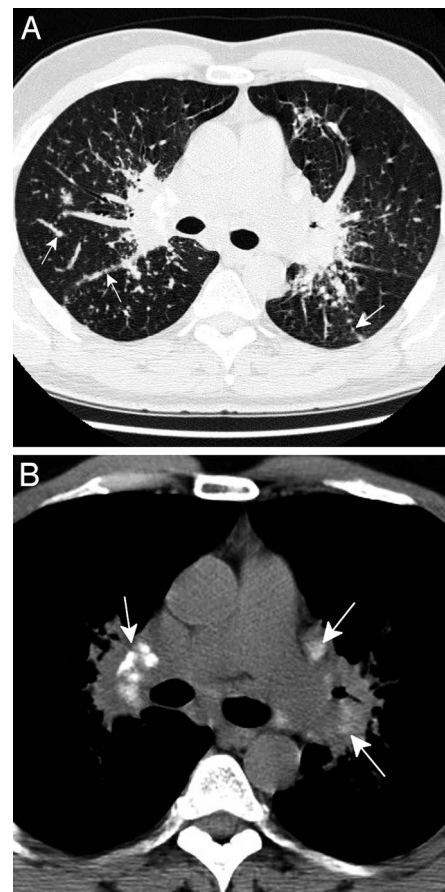
Excipient lung disease is another rare cause of centrilobular nodules in the setting of PH. This is secondary to the

intravenous injection of crushed oral tablets, usually narcotic pain killers. Excipients, including talc, microcrystalline cellulose, crospovidone, and starch, are insoluble inert filler materials that bind and protect the active drug.<sup>26</sup> When the drug is injected, this material embolizes into the pulmonary arterioles, inciting a granulomatous reaction in and around the vessel. As the pulmonary arteriole is in the center of the pulmonary lobule, this granulomatous reaction leads to diffuse ground glass nodules which involve the entire lung from the apices to the bases. In comparison to the centrilobular nodules seen in PAH and PCH, these nodules tend to be small and well defined (Figure 13).

Sarcoidosis is a multisystem disease characterized by noncaseating granulomatous inflammation which often manifests along and within the pulmonary vessels and airways as well as the subpleural interstitium. This inflammation creates small nodules in a perilymphatic distribution which are distinct from the centrilobular nodules seen on PAH and PCH (Figure 14). As discussed below, symmetric mediastinal and hilar lymphadenopathy and perihilar conglomerate fibrotic masses may develop over time. Sarcoidosis may contribute to PH via capillary destruction and alveolar hypoxia/hypoxic pulmonary vasoconstriction in the setting of fibrosis in late-stage (class 4) disease; however, the degree of PH in these patients is out of proportion to the degree of fibrosis in many patients, implicating additional mechanisms of SAPH including pulmonary vascular infiltration/obliteration by granulomatous inflammation, altered flow dynamics due to lymphadenopathy, and cardiac/extracardiac disease.<sup>27,28</sup>

#### *Mosaicism*

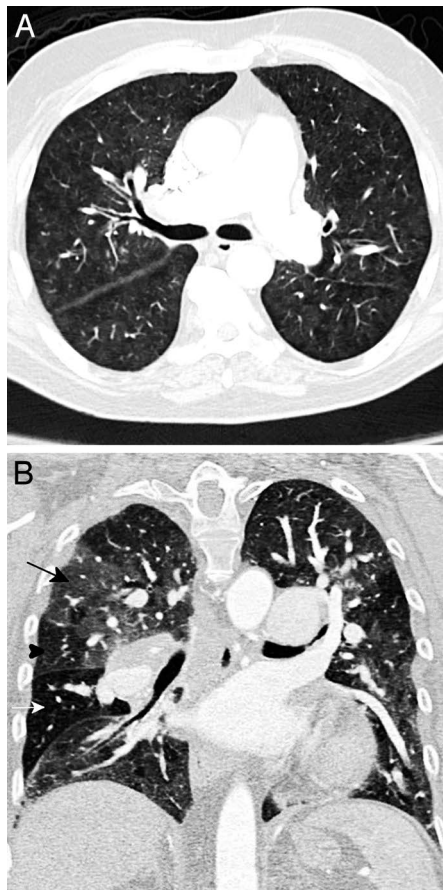
Specific patterns of a mosaic attenuation, defined as regional heterogeneity in pulmonary parenchymal attenuation, are characteristic for certain types of PH. Although any cause of PH can lead to a mosaic attenuation, PAH and CTEPH are the most common.<sup>29</sup> Mosaic attenuation, also referred to as “mosaic perfusion,” reflects regional difference in lung perfusion in patients with PH.<sup>30</sup> In PAH, mosaicism often manifests as



**Figure 14:** Pulmonary hypertension in a 49-year-old man with sarcoidosis. **(A)** Axial computed tomography in lung windows shows conglomerate perihilar soft tissue with extensive nodularity along the perilymphatic interstitial (white arrows). **(B)** Soft tissue window at the same level shows extensive symmetric mediastinal and hilar lymphadenopathy (white arrows). Many of the lymph nodes are calcified.

focal perivascular ground glass opacities, or small, scattered areas of increased attenuation often confined to center of the secondary pulmonary lobule<sup>31</sup> (Figure 15). In some instances, the perivascular hyperattenuation can appear as subtle ground glass centrilobular nodules as discussed above.

Compared to the mosaic pattern seen in PAH, the pattern in CTEPH often manifests as larger, regional areas of decreased attenuation that correspond to a vascular territory with associated narrowing or occlusion of the supplying vessel (Figure 15).<sup>32,33</sup> In severe cases of CTEPH, in addition to areas of hypoperfusion, segmental or subsegmental areas of hyperperfusion and increased attenuation can be present and reflect



**Figure 15:** Comparison of mosaic attenuation. (A) 33-year-old man with pulmonary arterial hypertension shows lobular areas of ground glass opacity directly adjacent to more lucent lung creating a mosaic attenuation. (B) In comparison, in chronic thromboembolic pulmonary hypertension, the mosaicism tends to be more well defined and corresponds to vascular distributions. An area of normal attenuation (black arrowhead) lies directly adjacent to an area of lobar, segmental, or subsegmental hypoperfusion (white arrow) inferiorly and hyperperfusion (black arrow), due to compensatory increased flow, superiorly.

shunting of blood to these nonoccluded regions. Within these areas of hyperperfusion, the corresponding vasculature is often engorged and increased in size compared to the adjacent bronchus reflecting increased blood flow (Figure 5).

PH due to left heart disease and PH due to lung disease and/or hypoxia are less likely to lead to a mosaic pattern.<sup>8</sup> These can usually be distinguished on imaging by the presence of ancillary findings, for example, dilated left atrium in the setting of mitral valve disease, presence of severe emphysema, fibro-

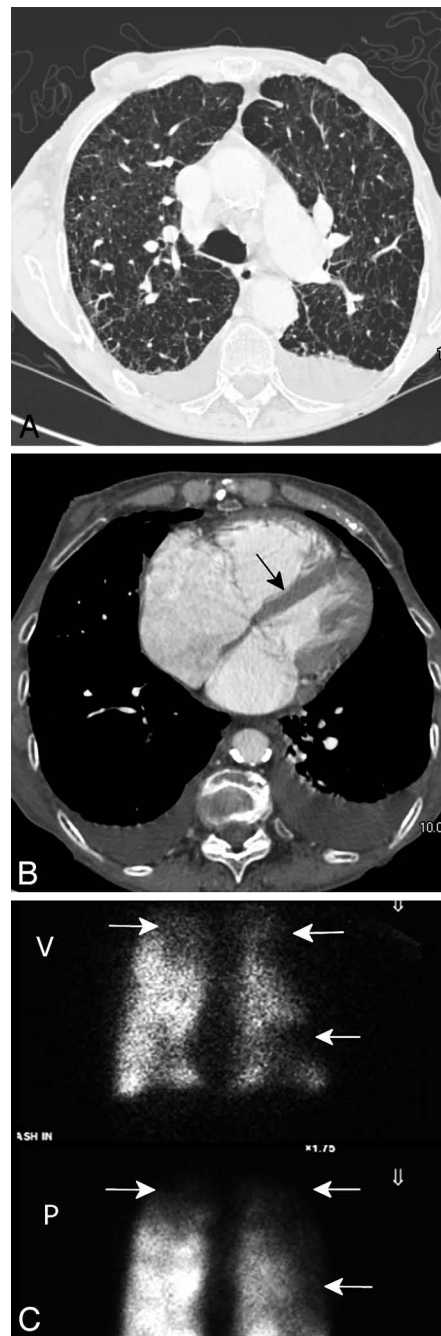
sis, or other lung disease, as discussed below. Therefore, the combination of PA enlargement and mosaic attenuation should prompt a careful search for ancillary findings to help narrow the differential diagnosis.

### *Emphysema*

The prevalence of PH in chronic obstructive pulmonary disease (COPD) varies from 50% in mild disease to 70% to 90% in severe disease.<sup>34</sup> The pathogenesis of PH in emphysema is multifactorial, resulting from destruction of the pulmonary vascular bed, vascular remodeling, endothelial dysfunction, and thrombosis.<sup>34,35</sup> The presence of PH is a poor prognostic indicator, and the 5-year survival rate was 36% for patients with a mean pulmonary arterial pressure >25 mm Hg in one series.<sup>36</sup> Over time, PH in patients with emphysema can lead to cor pulmonale and subsequent right heart failure<sup>37</sup> (Figure 16).

As emphysema is smoking related, findings are generally upper-lobe predominant. On CT, emphysema can be identified by abnormal lucency with a density less than -950 Hounsfield Units (HU), compared with a normal range -770 to -885 HU for lung parenchyma. The predominant finding of centrilobular emphysema is abnormal lucency in the central portion of secondary pulmonary lobules without a visible wall separating abnormal from normal lung parenchyma; the absence of a surrounding wall differentiates centrilobular emphysema from cystic lung disease. In severe disease, these spaces become extensive and confluent. Paraseptal emphysema typically involves the distal airways and is recognized by its involvement of the subpleural lung. Unlike centrilobular emphysema, the area of focal lucency may be surrounded by a thin wall. An area of paraseptal emphysema >1 cm is termed a bulla. Finally, in panlobular emphysema, there is uniform destruction of the pulmonary lobule; unlike other types of emphysema, panlobular emphysema tends to affect the entire lung uniformly or may be more basal predominant.

V/Q scintigraphy typically demonstrates in homogenous but matched upper lobe ventilation and perfusion



**Figure 16:** Pulmonary hypertension and cor pulmonale in a 75-year-old man with severe emphysema. (A) Axial computed tomography in lung windows shows extensive centrilobular emphysema. (B) Axial image through the heart shows right ventricular hypertrophy and dilation with flattening of the interventricular septum. The right atrium is also enlarged. (C) Ventilation/perfusion scan shows hyperinflated lungs with matched ventilation (V) and perfusion (P) defects, most notably in the upper lobes (white arrows) where the emphysema is most severe.



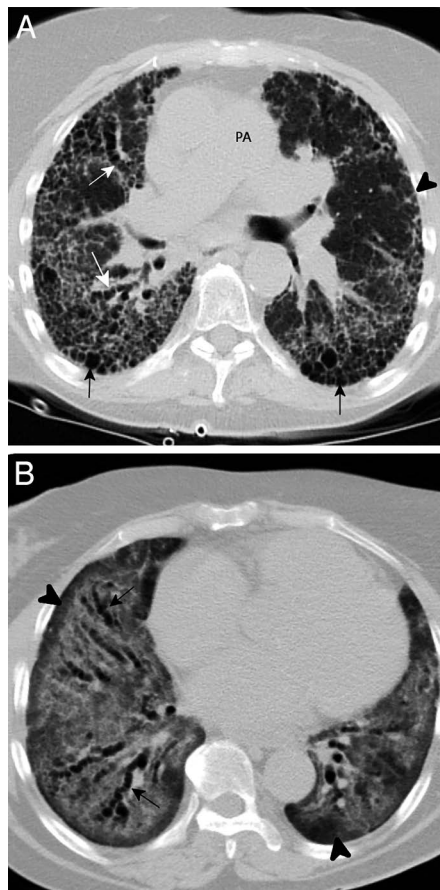
corresponding to areas of emphysema.<sup>38</sup> In some cases, a “stripe sign” may be seen, with centrally decreased perfusion and peripherally preserved perfusion, which is specific for centrilobular emphysema in COPD patients.<sup>39</sup>

### Fibrosis

Fibrosis is the common terminal stage in multiple interstitial lung diseases. Mechanisms of fibrosis related to growth factor release, fibroblast activation, and alterations to the endothelin system appear to be shared with the pathogenesis of PH.<sup>40</sup> While nearly any fibrotic lung disease can be associated with PH, those most commonly associated with PH include collagen vascular disease (particularly systemic sclerosis and rheumatoid arthritis), idiopathic pulmonary fibrosis, and sarcoidosis.<sup>40</sup>

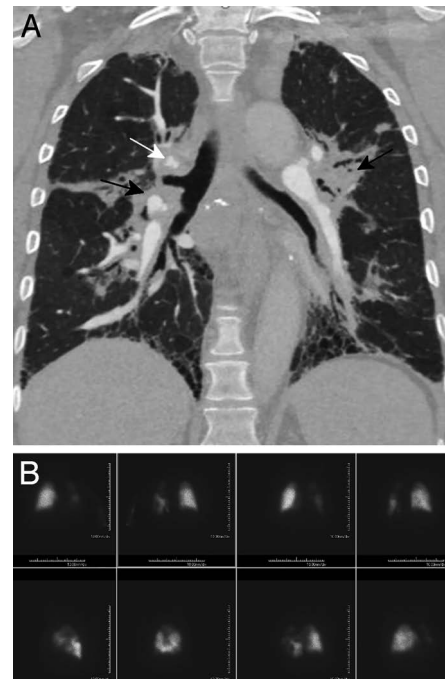
On both chest x-ray and high-resolution CT, fibrosis usually presents as areas of peripheral reticulation with associated volume loss. More severe fibrosis results in pronounced architectural distortion and widening of the airways, known as traction bronchiectasis. Severe fibrosis also results in honeycombing, represented by multilayered 3 mm to 2 cm cysts in a subpleural location. Two specific histologic patterns of lung disease which demonstrate some of these findings are usual interstitial pneumonia (UIP) and nonspecific interstitial pneumonia (NSIP).

A UIP pattern is seen in idiopathic pulmonary fibrosis (Figure 17) in addition to collagen vascular diseases, especially rheumatoid arthritis and scleroderma. This pattern is characterized by subpleural lower-lobe predominant peripheral reticulation, traction bronchiectasis, honeycombing, and extensive volume loss.<sup>41</sup> NSIP, which is the most common pattern of fibrotic lung disease seen in patients with collagen vascular diseases, usually demonstrates symmetric lower-lobe predominant peribronchiolar ground glass opacity extending toward the periphery with associated reticulation and traction bronchiectasis.<sup>42</sup> A characteristic feature of NSIP is the presence of subpleural sparing, distinguishing it from a UIP pattern (Figure 17). Differentiation between these two patterns can be difficult even for the most experienced radiologist.



**Figure 17:** Pulmonary hypertension associated with fibrosis. (A) Axial oblique image in a 63-year-old woman with idiopathic pulmonary fibrosis shows an enlarged pulmonary artery (PA) and a typical usual interstitial pneumonia pattern with lower lobe and subpleural predominant fibrosis as indicated by the presence reticulation (black arrowhead), traction bronchiectasis (white arrows), and honeycombing (black arrows). (B) Axial image in a 40-year-old woman with mixed connective tissue disease shows perihilar ground glass opacity with traction bronchiectasis (black arrows) and subpleural sparing (black arrowheads) characteristic of a nonspecific interstitial pneumonia pattern.

Compared to the lower-lobe predominant fibrosis seen in UIP and NSIP, the fibrosis in sarcoid is usually perihilar and upper lobe predominant (Figure 18). Perilymphatic nodules may be visualized in areas adjacent to the fibrosis. Less common parenchymal findings include fibrocystic lesions, which manifest as irregular bronchiectatic and cystic changes with an upper lobe predominance. Pulmonary V/Q scintigraphy is usually noncontributory in these patients, and on occasion, vascular narrowing or occlusion due to surrounding lymphadenopathy or perihilar fibrosis can

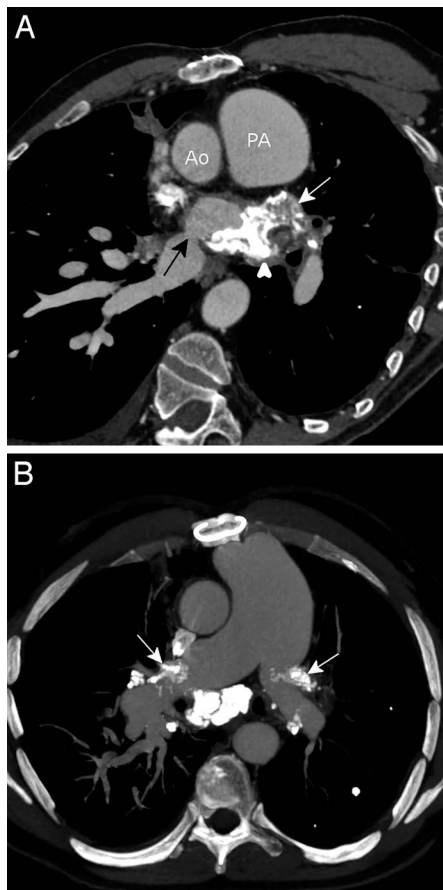


**Figure 18:** Pulmonary hypertension in fibrotic sarcoid. (A) Coronal image in a 57-year-old man with sarcoid shows extensive perihilar fibrotic changes (black arrows) with conglomerate soft tissue and traction bronchiectasis. In certain areas, the pulmonary artery branches are narrowed by the surrounding fibrosis (white arrow). No pulmonary emboli were present. (B) These areas of vascular compression led to multiple areas of ventilation/perfusion (V/Q) mismatch on V/Q scan which was interpreted as a high probability for pulmonary emboli.

mimic findings in CTEPH (Figure 18). Gallium single photon emission computed tomography imaging may also play a role in diagnosing sarcoidosis but is beyond the scope of this article.

### MEDIASTINUM

Careful evaluation of the mediastinum is important in patients undergoing imaging workup for PH, as mediastinal abnormalities may implicate alternative, multifactorial diagnoses. Fibrosing mediastinitis (FM) is a rare but serious—and sometimes fatal—disease with focal granulomatous and diffuse non-granulomatous subtypes; diffuse disease is characterized by florid inflammation and fibrous proliferation within the mediastinum, which results in encasement and extrinsic compression of mediastinal structures including airways and vascular structures.<sup>43–45</sup> Vascular manifestations most commonly involve the superior



**Figure 19:** Pulmonary hypertension in fibrosing mediastinitis (FM). (A) Axial oblique image through the left atrium shows a confluent, predominantly calcified soft tissue mass surrounding and compressing the left atrium due to FM. The ostia of the left superior (white arrow), left inferior (white arrowhead), and right superior (not shown) pulmonary veins were completely obstructed by FM. The ostium of the right inferior pulmonary vein is severely narrowed but patent (black arrow). The pronounced pulmonary venous obstruction was the cause of the patient's severe pulmonary hypertension as evidenced by the markedly enlarged main pulmonary artery (PA) which is much larger than the adjacent ascending aorta (Ao). (B) Axial oblique maximum intensity projection image shows a markedly enlarged main PA. Confluent predominantly calcified soft tissue fills the mediastinum with mild narrowing of the left and right main PAs (white arrows). The patient died a few months after the exam.

vena cava (SVC) which may result in SVC syndrome. Pulmonary arterial/venous stenoses or even occlusions can be seen in these patients, which can lead to precapillary and/or postcapillary forms of PH (Figure 19).<sup>44</sup>

Focal/granulomatous FM is most often associated with *Histoplasma* or

tuberculosis infection, with rupture of the encapsulated granuloma thought to trigger an intense fibroinflammatory response in some patients, but diffuse disease can be secondary to myriad causes including trauma, prior radiation therapy, autoimmune disease (eg, rheumatoid arthritis and systemic lupus erythematosus), sarcoidosis, Behçet Disease, sclerosing neoplasm, or may be idiopathic.<sup>45</sup>

Classically, CT will demonstrate an infiltrative middle mediastinal soft tissue mass with encasement of adjacent structures (Figure 19). Pulmonary arterial abnormalities are typically central in distribution (ie, main, lobar, or segmental) with architectural distortion secondary to fibrosis, inducing irregular arterial narrowing and peripheral soft tissue thickening. Pulmonary venous involvement may be characterized by soft tissue encasement of central pulmonary veins, juxta-ostial or perivenous masslike tissue resulting in stenosis or occlusion, and can be quite dramatic with a pronounced, abrupt “shoulder.” Findings of pulmonary edema, including interlobular septal/peribronchial thickening and centrilobular ground-glass opacities, are common in these patients and, when due to PA or vein stenosis, may be geographic depending on the level of obstruction.<sup>44</sup> Secondary pulmonary venous infarcts manifest like pulmonary infarcts associated with acute pulmonary embolism, as peripheral, wedge-shaped opacities that may demonstrate central clearing. Scarring secondary to chronic infarcts often demonstrates an atypical distribution with parenchymal bands and peripheral/subpleural reticulation.<sup>46</sup> Other CT findings associated with FM include diffuse mediastinal fat stranding/inflammatory change, calcified mediastinal/hilar lymph nodes, and pleural and/or pericardial effusions.

FM can mimic both CTEPH and vasculitis. The geographic areas of perfusion abnormality seen in FM may mimic CTEPH on V/Q scintigraphy, yet this distinction is crucial. While peripheral lobar thrombus in CTEPH may demonstrate a similar appearance, the other characteristic CTEPH findings of weblike filling defects and segmental and subsegmental occlusions will

be absent in FM. There is no adequate medical treatment for FM, and currently favored treatment modalities include endovascular angioplasty and/or stenting versus meticulous surgical dissection; however, attempted surgical dissection of the fibrotic rind seen in FM can be extremely difficult and is associated with high perioperative morbidity/mortality.<sup>45</sup> If these patients are misdiagnosed as having CTEPH, attempted pulmonary thromboendarterectomy can have devastating consequences. Distinguishing FM from vasculitis is also important, and the presence of alternating tapering/dilation of vessels and/or extrapulmonary vascular structures are highly suggestive of a vasculitis.

Mediastinal involvement with sarcoidosis most typically manifests as relatively symmetric enlargement of hilar and mediastinal lymph nodes with or without concomitant pulmonary parenchymal findings depending on the stage of the disease (Figure 14). Hilar and mediastinal lymphadenopathy is also a common finding in PVOD and is secondary to lymphatic congestion and vascular transformation of the sinuses, intrasinus hemorrhage, and lymphoid follicular hyperplasia<sup>47</sup> (Figure 10). However, PVOD and sarcoid can usually be distinguished from one another through associated parenchymal findings as discussed above.

Finally, specific attention should be given to the esophagus. As mentioned above, FM may result in esophageal compression and upstream dilation. Alternatively, a patulous/dilated esophagus may be seen in the setting of scleroderma, a rare multisystem autoimmune disease that includes PAH in approximately 13% of patients (Figure 12). Interestingly, while patients with PAH related to scleroderma typically have slightly lower mean pulmonary arterial pressure compared to patients with idiopathic PAH, they have higher morbidity/mortality, poorer response to therapy, and worse outcomes than patients with idiopathic PAH, though the pathophysiology and mechanisms underlying these differences have not been entirely elucidated.<sup>48</sup>

## CONCLUSION

The diagnosis of PH should initiate a multidisciplinary workup to elucidate

an underlying cause. Imaging, especially CT, plays an integral part in the initial evaluation. Careful assessment of the pulmonary and systemic vasculature, heart, lungs, and mediastinum allows for one to piece together various clues and make the correct diagnosis, optimizing patient care.

## References

- Simonneau G, Montani D, Celermajer DS, et al. Haemodynamic definitions and updated clinical classification of pulmonary hypertension. *Eur Respir J*. 2019;53(1).
- Kligerman SJ, Henry T, Lin CT, Franks TJ, Galvin JR. Mosaic attenuation: etiology, methods of differentiation, and pitfalls. *Radiographics*. 2015;35(5):1360–1380.
- Tan RT, Kuzo R, Goodman LR, Siegel R, Haasler GB, Presberg KW. Utility of CT scan evaluation for predicting pulmonary hypertension in patients with parenchymal lung disease. Medical College of Wisconsin Lung Transplant Group. *Chest*. 1998;113(5):1250–1256.
- Truong QA, Massaro JM, Rogers IS, et al. Reference values for normal pulmonary artery dimensions by noncontrast cardiac computed tomography: the Framingham Heart Study. *Circ Cardiovasc Imaging*. 2012;5(1):147–154.
- Devaraj A, Wells AU, Meister MG, Corte TJ, Wort SJ, Hansell DM. Detection of pulmonary hypertension with multidetector CT and echocardiography alone and in combination. *Radiology*. 2010;254(2):609–616.
- Ng CS, Wells AU, Padley SP. A CT sign of chronic pulmonary arterial hypertension: the ratio of main pulmonary artery to aortic diameter. *J Thorac Imaging*. 1999;14(4):270–278.
- Jenkins DP, Madani M, Mayer E, et al. Surgical treatment of chronic thromboembolic pulmonary hypertension. *Eur Respir J*. 2013;41(3):735–742.
- Sherrick AD, Swensen SJ, Hartman TE. Mosaic pattern of lung attenuation on CT scans: frequency among patients with pulmonary artery hypertension of different causes. *AJR Am J Roentgenol*. 1997;169(1):79–82.
- Wittram C, Kalra MK, Maher MM, Greenfield A, McLoud TC, Shepard JA. Acute and chronic pulmonary emboli: angiography-CT correlation. *AJR Am J Roentgenol*. 2006;186(6 Suppl 2):S421–S429.
- King MA, Ysrael M, Bergin CJ. Chronic thromboembolic pulmonary hypertension: CT findings. *AJR Am J Roentgenol*. 1998;170(4):955–960.
- Gan HL, Zhang JQ, Huang XY, Yu W. The wall eclipsing sign on pulmonary artery computed tomography angiography is pathognomonic for pulmonary artery sarcoma. *PLoS ONE*. 2013;8(12):e83200.
- Bandyopadhyay D, Panchabhavi TS, Bajaj NS, Patil PD, Bunte MC. Primary pulmonary artery sarcoma: a close associate of pulmonary embolism—20-year observational analysis. *J Thorac Dis*. 2016;8(9):2592–2601.
- Peña E, Dennie C, Veinot J, Muñiz SH. Pulmonary hypertension: how the radiologist can help. *Radiographics*. 2012;32(1):9–32.
- Aviram G, Cohen D, Steinvil A, et al. Significance of reflux of contrast medium into the inferior vena cava on computerized tomographic pulmonary angiogram. *Am J Cardiol*. 2012;109(3):432–437.
- Aluja Jaramillo F, Gutierrez FR, Díaz Telli FG, Yevenes Aravena S, Javidan-Nejad C, Bhalla S. Approach to pulmonary hypertension: from CT to clinical diagnosis. *Radiographics*. 2018;38(2):357–373.
- Frazier AA, Franks TJ, Mohammed TL, Ozbudak IH, Galvin JR. From the archives of the AFIP: pulmonary veno-occlusive disease and pulmonary capillary hemangiomatosis. *Radiographics*. 2007;27(3):867–882.
- Resten A, Maitre S, Humbert M, et al. Pulmonary hypertension: CT of the chest in pulmonary venoocclusive disease. *AJR Am J Roentgenol*. 2004;183(1):65–70.
- Montani D, Achouh L, Dorfmueller P, et al. Pulmonary veno-occlusive disease: clinical, functional, radiologic, and hemodynamic characteristics and outcome of 24 cases confirmed by histology. *Medicine (Baltimore)*. 2008;87(4):220–233.
- Seferian A, Helal B, Jaïs X, et al. Ventilation/perfusion lung scan in pulmonary veno-occlusive disease. *Eur Respir J*. 2012;40(1):75–83.
- Corte TJ, Wells AU, Nicholson AG, Hansell DM, Wort SJ. Pulmonary hypertension in sarcoidosis: a review. *Respirology*. 2011;16(1):69–77.
- O’Keefe MC, Post MD. Pulmonary capillary hemangiomatosis: a rare cause of pulmonary hypertension. *Arch Pathol Lab Med*. 2015;139(2):274–277.
- Simonneau G, Montani D, Celermajer DS, et al. Haemodynamic definitions and updated clinical classification of pulmonary hypertension. *Eur Respir J*. 2019;53(1).
- Szturmowicz M, Kacprzak A, Burakowska B, et al. Centrilobular nodules in high resolution computed tomography of the lung in IPAH patients—preliminary data concerning clinico-radiological correlates. *Pneumonol Alergol Pol*. 2016;84(5):265–270.
- Devaraj A, Hansell DM. Computed tomography signs of pulmonary hypertension: old and new observations. *Clin Radiol*. 2009;64(8):751–760.
- Nolan RL, McAdams HP, Sporn TA, Roggli VL, Tapsos VF, Goodman PC. Pulmonary cholesterol granulomas in patients with pulmonary artery hypertension: chest radiographic and CT findings. *AJR Am J Roentgenol*. 1999;172(5):1317–1319.
- Nguyen VT, Chan ES, Chou SH, et al. Pulmonary effects of i.v. injection of crushed oral tablets: “excipient lung disease”. *AJR Am J Roentgenol*. 2014;203(5):W506–W515.
- Nunes H, Humbert M, Capron F, et al. Pulmonary hypertension associated with sarcoidosis: mechanisms, haemodynamics and prognosis. *Thorax*. 2006;61(1):68–74.
- Duong H, Bonham CA. Sarcoidosis-associated pulmonary hypertension: pathophysiology, diagnosis, and treatment. *Clin Pulm Med*. 2018;25(2):52–60.
- Worthy SA, Müller NL, Hartman TE, Swensen SJ, Padley SP, Hansell DM. Mosaic attenuation pattern on thin-section CT scans of the lung: differentiation among infiltrative lung, airway, and vascular diseases as a cause. *Radiology*. 1997;205(2):465–470.
- Stern EJ, Swensen SJ, Hartman TE, Frank MS. CT mosaic pattern of lung attenuation: distinguishing different causes. *Am J Roentgenol*. 1995;165(4):813–816.
- Grosse C, Grosse A. CT findings in diseases associated with pulmonary hypertension: a current review. *Radiographics*. 2010;30(7):1753–1777.
- Schwicker HC, Schweden F, Schild HH, et al. Pulmonary arteries and lung parenchyma in chronic pulmonary embolism: preoperative and postoperative CT findings. *Radiology*. 1994;191(2):351–357.
- Bergin CJ, Rios G, King MA, Belezouli E, Luna J, Auger WR. Accuracy of high-resolution CT in identifying chronic pulmonary thromboembolic disease. *AJR Am J Roentgenol*. 1996;166(6):1371–1377.
- Chaouat A, Nacije R, Weitzenblum E. Pulmonary hypertension in COPD. *Eur Respir J*. 2008;32(5):1371–1385.
- Shujaat A, Bajwa AA, Cury JD. Pulmonary hypertension secondary to COPD. *Pulm Med*. 2012;2012:203952.
- Oswald-Mammoser M, Weitzenblum E, Quoix E, et al. Prognostic factors in COPD patients receiving long-term oxygen therapy. Importance of pulmonary artery pressure. *Chest*. 1995;107(5):1193–1198.
- MacNee W. Pathophysiology of cor pulmonale in chronic obstructive pulmonary disease. Part One. *Am J Respir Crit Care Med*. 1994;150(3):833–852.
- Sinzinger H, Rodrigues M, Kummer F. Ventilation/perfusion lung scintigraphy. Multiple applications besides pulmonary embolism. *Hell J Nucl Med*. 2013;16(1):50–55.
- Mortensen J, Berg RMG. Lung scintigraphy in COPD. *Semin Nucl Med*. 2019;49(1):16–21.
- Behr J, Ryu JH. Pulmonary hypertension in interstitial lung disease. *Eur Respir J*. 2008;31(6):1357–1367.
- Raghu G, Remy-Jardin M, Myers JL, et al. Diagnosis of idiopathic pulmonary fibrosis. An official ATS/ERS/JRS/ALAT Clinical Practice Guideline. *Am J Respir Crit Care Med*. 2018;198(5):e44–e68.
- Kligerman SJ, Groshong S, Brown KK, Lynch DA. Nonspecific interstitial pneumonia: radiologic, clinical, and pathologic considerations. *Radiographics*. 2009;29(1):73–87.
- Makhija Z, Murgatroyd F, Gall N, Marrinan MT, Deshpande R, Desai SR. Fibrosing mediastinitis and occlusion of pulmonary veins

- after radiofrequency ablation. *Ann Thorac Surg.* 2009;88(5):1674–1676.
44. Seferian A, Steriade A, Jais X, et al. Pulmonary hypertension complicating fibrosing mediastinitis. *Medicine (Baltimore).* 2015;94(44):e1800.
45. Rossi SE, McAdams HP, Rosado-de-Christenson ML, Franks TJ, Galvin JR. Fibrosing mediastinitis. *Radiographics.* 2001;21(3):737–757.
46. Kwon MR, Lee HY, Cho JH, Um SW. Lung infarction due to pulmonary vein stenosis after ablation therapy for atrial fibrillation misdiagnosed as organizing pneumonia: sequential changes on CT in two cases. *Korean J Radiol.* 2015;16(4):942–946.
47. Thomas de Montpréville V, Dulmet E, Fadel E, Dartevelle P. Lymph node pathology in pulmonary veno-occlusive disease and pulmonary capillary hemangiomas. *Virchows Arch.* 2008;453(2):171–176.
48. Fisher MR, Mathai SC, Champion HC, et al. Clinical differences between idiopathic and scleroderma-related pulmonary hypertension. *Arthritis Rheum.* 2006;54(9):3043–3050.

# The Future of Imaging in Pulmonary Hypertension: Better Assessment of Structure, Function, and Flow

Akhil Narang, MD  
*Division of Cardiology, Department of  
Medicine  
Feinberg Cardiovascular Research Institute  
Northwestern University Feinberg School  
of Medicine  
Chicago, IL*

Benjamin H. Freed, MD  
*Division of Cardiology, Department of  
Medicine  
Feinberg Cardiovascular Research Institute  
Northwestern University Feinberg School  
of Medicine  
Chicago, IL*

Cardiovascular imaging is essential in the evaluation and management of patients with pulmonary hypertension. Echocardiography and magnetic resonance imaging, in particular, provide basic measurements of pulmonary pressure and right ventricular function, but current technology allows for a much more comprehensive assessment. Many of these advancements have the potential to enhance risk stratification and provide additional phenotypic data that may strengthen or alter the therapeutic approach. This review will highlight multiple novel techniques from various imaging modalities and how this information can be applied in clinical practice.

---

## INTRODUCTION

The standard imaging evaluation of patients with known or presumed pulmonary hypertension (PH) includes the measurement of pulmonary arterial systolic pressure and the assessment of right ventricular (RV) size and function. While this information is certainly critical for the management of these patients, it is the very minimum of what current imaging technology can provide. Today, imaging modalities such as echocardiography and magnetic resonance imaging (MRI) can probe the pulmonary vasculature and deconstruct RV movement in new and exciting ways, providing greater mechanistic insight into the pathophysiology of this disease and a better understanding of how current therapies work. This review will focus on novel imaging techniques in PH, which have the potential to fundamentally change how we care for these patients.

## ECHOCARDIOGRAPHY

Mortality and morbidity of patients with PH is closely linked to the function and size of the RV. Accordingly, echocardiographic evaluation of patients

with known or suspected PH centers on attempts to accurately understand the RV. The anterior location of the RV within the thorax coupled with its complex geometry make echocardiographic assessment particularly challenging. No single echocardiographic view adequately captures the entirety of the chamber, either anatomically or with respect to functional analysis. Moreover, the complicated contraction of the RV (longitudinal fiber shortening along the lateral tricuspid annulus towards the apex, free wall inward movement or “bellows effect,” and anteroposterior free wall shortening over the shared ventricular septum) have resulted in the development of multiple quantitative parameters.<sup>1,2</sup>

### *General Echocardiographic Analysis*

Conventional echocardiographic assessment of RV size and function incorporates a number of 1- and 2-dimensional (2D) indices.<sup>3</sup> Size of the RV is often assessed using linear dimensions of the RV from a number of views including parasternal and apical views. RV function is often qualitatively evaluated,

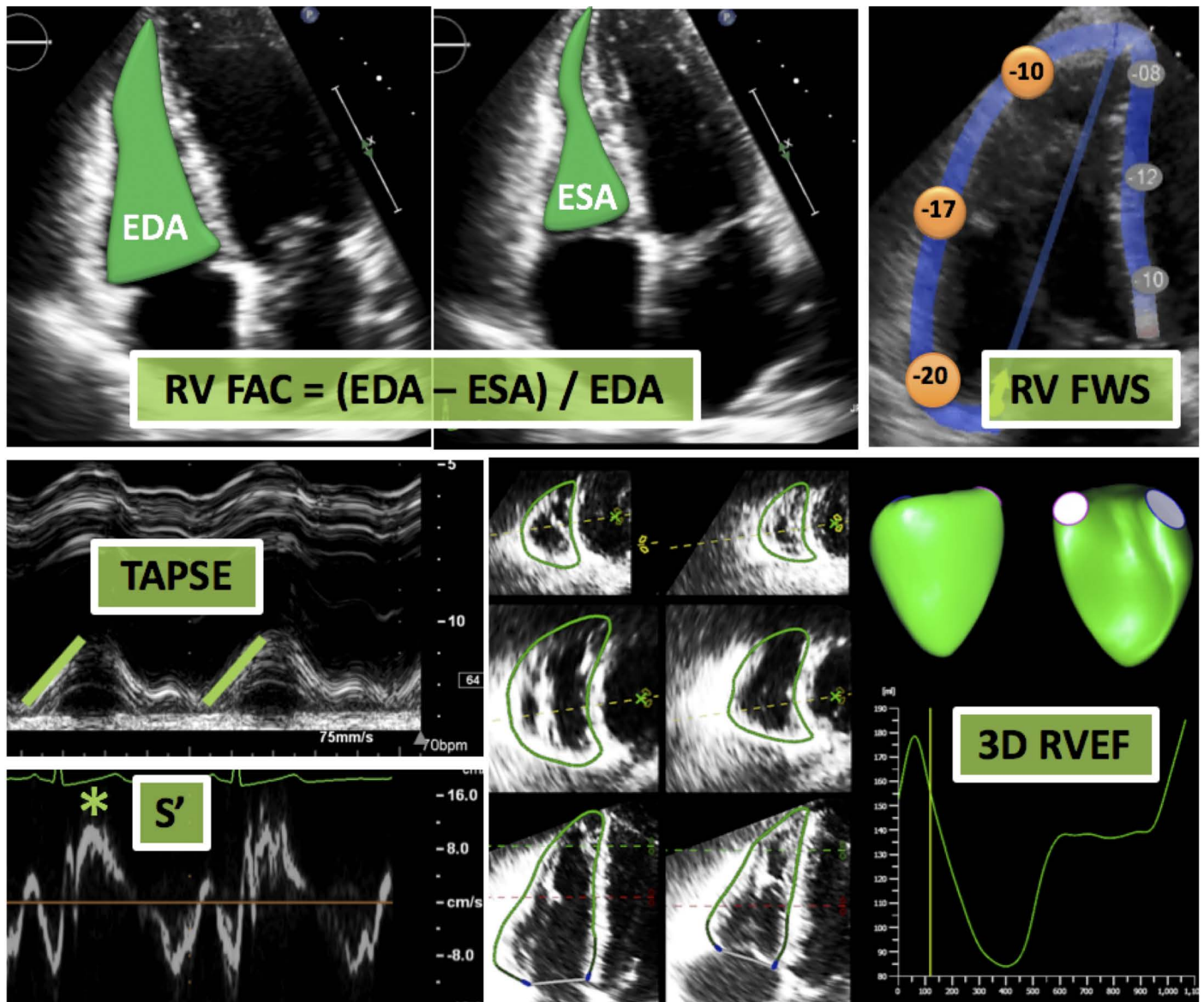
though this is subject to considerable inter- and intra-observer variability. Quantitative assessment of RV function can be accomplished through several different techniques, most commonly: tricuspid annular plane systolic excursion (TAPSE), S' velocity, and fractional area change (FAC).

TAPSE (M-mode) reflects the basal to apical shortening or distance traveled of the lateral tricuspid valve annulus between end-diastole and end-systole while S' (tissue Doppler imaging) measures the myocardial systolic excursion velocity at lateral tricuspid annulus. Both TAPSE and S' primarily evaluate the longitudinal motion of the RV free wall while not incorporating the other aspects of RV contraction. Both of these parameters are also angle dependent and do not fully account for global RV function. RV FAC better reflects global RV function and relies upon accurate tracing of the RV end-diastolic area (EDA) and end-systolic area (ESA) where  $FAC = (EDA - ESA)/EDA$ .

Furthermore, beyond evaluation of RV systolic pressure and pulmonary artery (PA) pressures using Doppler echocardiography (through assessment of the RV-right atrial gradient or pulmonary regurgitation signal and modified Bernoulli equation), a complete noninvasive hemodynamic assessment is possible

---

Key Words—pulmonary hypertension, right ventricle, echocardiography, MRI, pulmonary vasculature  
Correspondence: benjamin.freed@northwestern.edu  
Disclosure: The authors have no relevant personal financial relationships to disclose.



**Figure 1:** Echocardiographic assessment of RV function. RV = right ventricle; FAC = fractional area change; EDA = end-diastolic area; ESA = end-systolic area; FWS = free wall strain; TAPSE = tricuspid annular plane systolic excursion; 3D = 3-dimensional; RVEF = right ventricular ejection fraction.

and should routinely be performed. These parameters include right atrial pressure, pulmonary vascular resistance, and evaluation of left-sided pressures. Furthermore, other echocardiographic parameters such as a reduced PA acceleration time (pulsed-wave Doppler) and notching of the right ventricular outflow tract Doppler tracing are markers of significant PH.<sup>4</sup>

While these conventional echocardiographic RV parameters are helpful in understanding downstream consequences of PH on the size and function of the RV, each have their shortcomings. In recent times, there is emerging data

on the use of novel echocardiographic indices that, when coupled with conventional assessment, further enable the clinician to interrogate the sequelae of PH (Figure 1).

#### *Three-Dimensional (3D) Echocardiography*

The development and refinement of 3D echocardiography over the past several decades have allowed for tremendous progress in our understanding of the RV.<sup>5,6</sup> Through the transthoracic acquisition of a pyramid of ultrasound data, there is now the capability to obtain accurate volumetric measurements of the

RV, which much more closely reflect the “gold standard” of MRI.

Previous studies have confirmed 3D RV volumes measured by echocardiography better correlate with MRI measured volumes than 2D RV echocardiography volumes.<sup>7-9</sup> Accordingly, the calculation of 3D RV ejection fraction (EF) derived from 3D volumes represents another important index to evaluate RV size and function. 3D RVEF is the only parameter that fully incorporates global RV function throughout the cardiac cycle. Serial interrogation of 3D RV volumes and EF in response to therapies for PH (including diuretics) may yield import-

ant data that reflect RV remodeling over time. Adequate interpretation and analysis of 3D volume acquisitions of the RV depends on user experience and training and is often a barrier to widespread adaptation. The advent of artificial intelligence and machine learning may allow for greater incorporation of 3D echocardiography. Once 3D images are acquired, automated postprocessing analysis generates RV volumes and EF that are comparable to MRI assessment.<sup>10</sup>

### *RV Shape*

Remodeling of the RV in PH is also best understood using 3D echocardiography. 3D RV full-volume acquisitions can be segmented into endocardial surfaces from which RV shape can be determined. Parameters from these surface maps, namely curvature, are then quantifiable. In patients with PH, the RV septum is convex in curvature and bulges toward the left ventricle throughout the cardiac cycle unlike in normal subjects. Additionally, in PH (unlike healthy controls), the RV free wall and apex demonstrate convexity throughout the cardiac cycle.<sup>11–13</sup> Temporal changes in these differential, regional curvature changes during the course of therapy may be a useful means of monitoring disease progression or regression.

### *Tricuspid Regurgitation*

In patients with progressive PH, functional tricuspid regurgitation often results as a consequence of RV and tricuspid annular remodeling. The progression of tricuspid regurgitation in PH has been shown to be associated with progressive increasing all-cause mortality. From an echocardiographic standpoint, progressive tricuspid regurgitation has been associated with higher PA pressures, increasing RV enlargement, worsening RV sphericity, tricuspid annular dilation, and increasing tricuspid valve tenting area. Patients who experience worsening tricuspid regurgitation in serial imaging warrant special attention as this may suggest worse outcomes.<sup>14</sup>

### *RV Strain*

Myocardial deformation analysis is the underlying principle of strain. Speck-

le-tracking echocardiography (STE) is the predominant method by which strain is calculated. STE relies on tracking motion of ultrasound speckles throughout the cardiac cycle. The speckles are created as a result of ultrasound beam scatter and can be identified frame by frame as they move across systole and diastole. Tracking these speckles allows for the creation of strain and strain rate curves. STE relies on imaging at high frame rates, typically >50 frames/second. There are a number of benefits of strain imaging, namely that measurements generally reflect global function (accounting for abnormalities that occur throughout the cardiac cycle), and strain is angle- and mostly load-independent.<sup>15</sup>

Unlike the left ventricle, where longitudinal, circumferential, and radial strain are all useful parameters of myocardial deformation, the longitudinal strain of the RV best reflects the underlying myocardial fiber architecture of the RV. Furthermore, due to the shared septum between the right and left ventricles, the septal contribution to RV strain is typically ignored in favor of using the longitudinal strain of the RV free wall.

In patients with seemingly normal parameters of RV function, abnormalities in RV free wall longitudinal strain often reflect subclinical RV dysfunction before it may be readily apparent or measured by 1 or 2D echocardiographic parameters. Similarly, the RV free wall can be subdivided into the basal, mid, and apical segments. Regional RV remodeling in PH, in addition to other pathologies, can also be detected by regional strain changes.

In PH, abnormal RV free wall strain has been associated with worse outcomes and New York Heart Association functional class. The cutoff values for RV strain in PH vary from study to study, but improvements in strain are generally observed in response to medical therapy.<sup>16–18</sup> Worsening RV strain despite medical therapy should be seen as a sign of possible RV failure.

### *Impact on the Left Ventricle*

While PH is primarily thought of as a disease of the right heart, its impact on the left ventricle has recently become clearer. Generally the left ventricular

(LV) EF is preserved in PH, so when significant reduction in LVEF occurs, the prognosis is often dismal. However, when the LVEF is normal, newer work has shown LV global longitudinal strain is independently associated with death in addition to right-sided heart abnormalities.<sup>19</sup> In addition to routine assessment of RV strain, consideration should be given to following LV strain as well.

### **MRI**

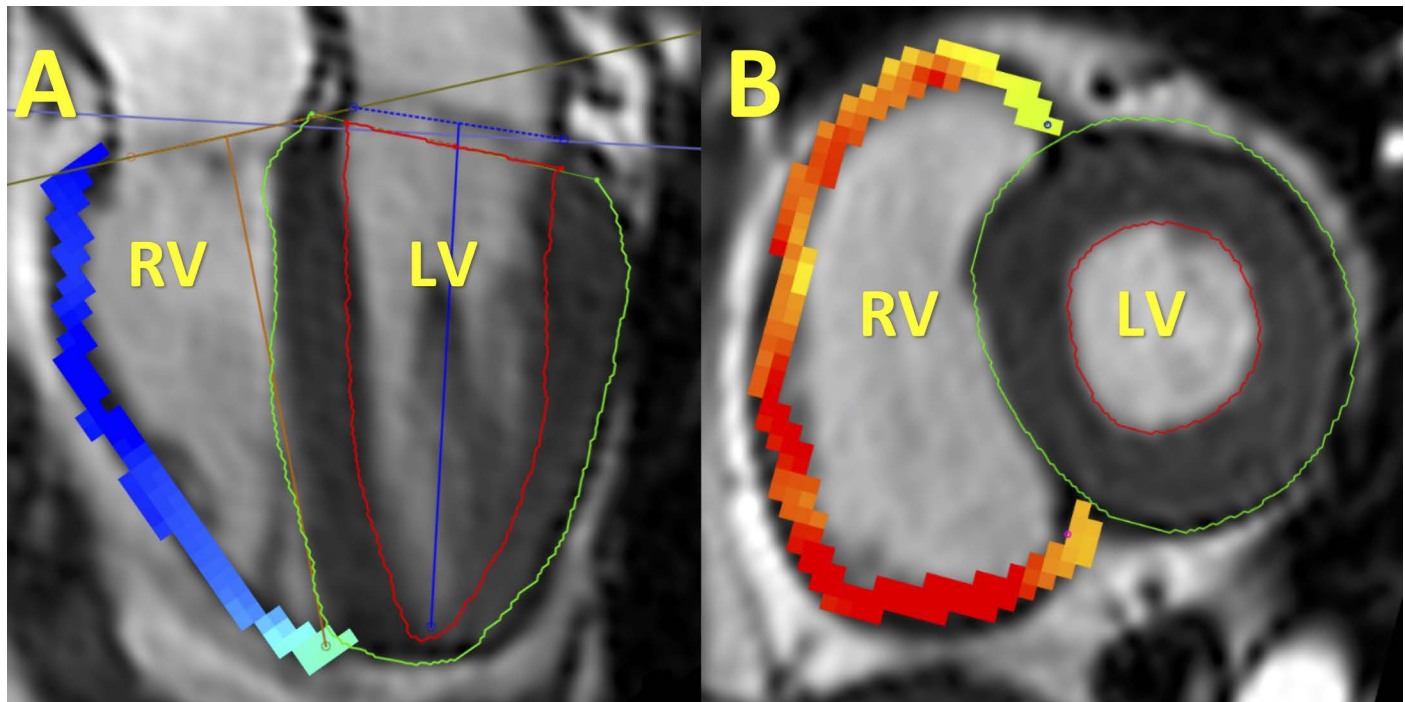
The role for MRI in the evaluation of patients with PH is rapidly evolving. MRI is already considered the “gold standard” for assessment of RV volume, mass, and EF, and the prognostic utility of all of these measures in PH is well established.<sup>20</sup> In addition, MRI measurements of the pulmonary vasculature, including PA velocity, flow, and stiffness, have provided insights into the pathophysiology of PH and all show promise in the clinical workup of patients with this disease.<sup>20</sup> This review will highlight newer MRI techniques such as RV strain imaging, RV T1 mapping, and 4-dimensional (4D) flow of the pulmonary vasculature that move beyond standard cine and 2D phase contrast imaging. The use of exercise MRI and deep learning will also be discussed.

### *RV Strain Imaging*

As mentioned earlier, strain imaging measures myocardial deformation and is potentially a more sensitive metric of cardiac function than EF. RV strain is a strong predictor of outcomes in PH and adds incremental prognostic value to PA systolic pressure and other clinical variables.<sup>16,21,22</sup> Given its ability to provide volumetric coverage of the whole heart, MRI is uniquely positioned to evaluate RV strain in a number of cardiac conditions including PH.

One of the first publications to evaluate RV strain in PH showed reduced longitudinal strain in several RV segments despite normal RVEF, highlighting the superior sensitivity of RV strain to detect regional changes in function.<sup>23</sup> This study used strain encoded imaging which requires dedicated image acquisitions.

More recently, feature-tracking strain, which can be performed retro-



**Figure 2:** Feature tracking strain of the LV and RV. (A) RV and LV longitudinal strain analysis obtained from a four-chamber view. (B) RV and LV radial strain analysis obtained from a short-axis view. Strain analysis was performed on the software cvi42 by Circle Cardiovascular Imaging Inc, release 5.3.0 (364). RV = right ventricle; LV = left ventricle.

spectively using standard cine images, has shown promise in measuring RV strain (Figure 2, see also Supplemental Clips 1 and 2). In a study evaluating over 100 patients referred to MRI for PH evaluation, feature-tracking RV strain was feasible in 95% of patients and showed significantly reduced global circumferential strain rate in patients with normal RVEF.<sup>24</sup> Furthermore, RV strain was independently associated with the composite endpoint of death, lung transplantation, or functional class deterioration.

Tello et al. used pressure-volume loop measurements to help determine which RV indices are most associated with strain. In a study of 38 patients with PH who underwent conductance catheterization within 24 hours of feature-tracking RV strain, long-axis RV radial strain was associated with RV-PA coupling while RV longitudinal strain showed a significant association with RV end-diastolic stiffness.<sup>25</sup>

#### *RV T1 Mapping*

One of the most unique capabilities of MRI is characterizing tissue abnormalities using gadolinium contrast. In PH, late gadolinium enhancement is

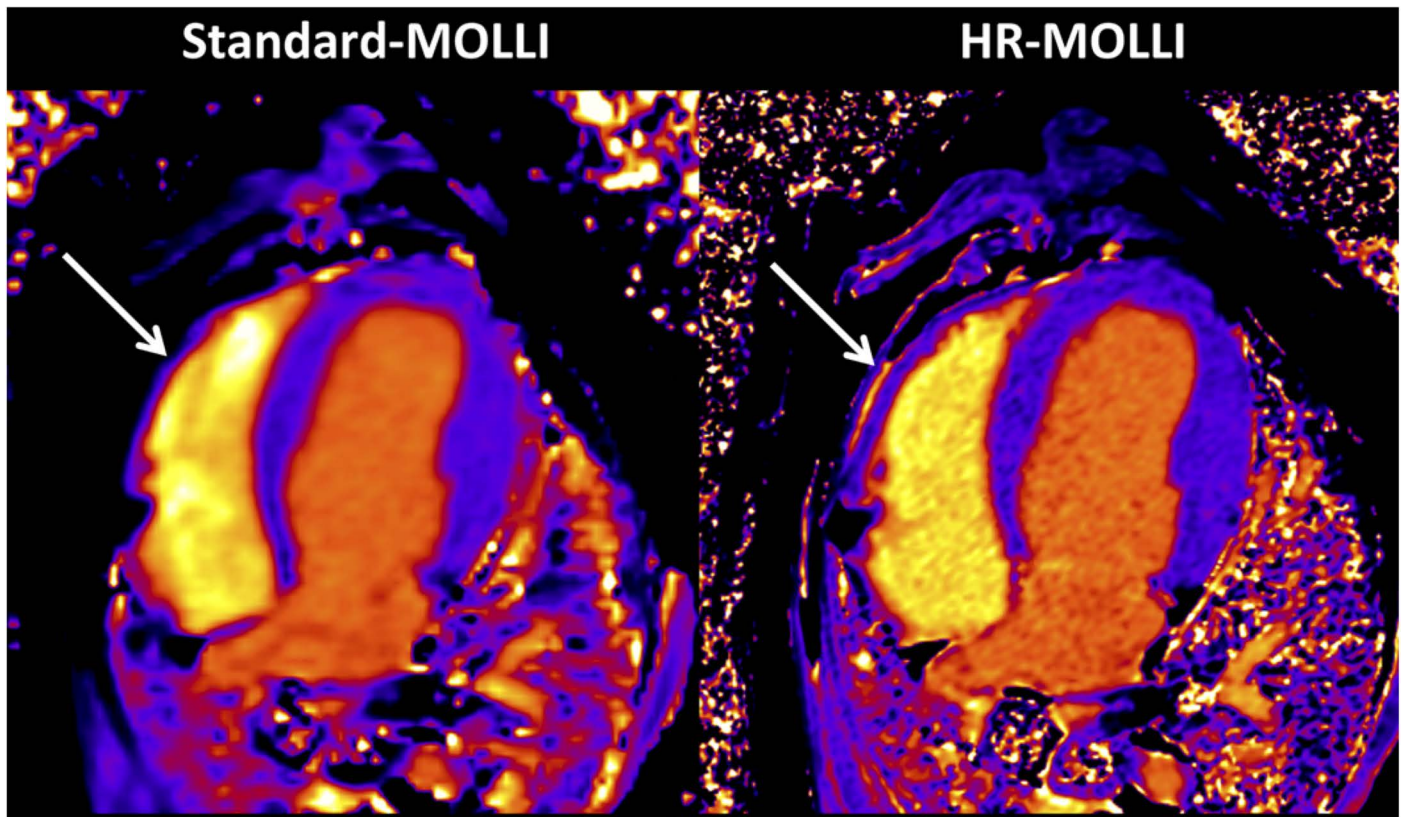
frequently detected in the RV insertion points, likely due to RV remodeling.<sup>26</sup> While commonly observed in this patient population, RV insertion point enhancement is rather nonspecific and is not independently associated with poor outcomes.<sup>27,28</sup> Recent work has focused on RV T1 mapping, a technique that allows for quantitative measurement of diffuse interstitial fibrosis in the RV. Several PH studies show a significant association between RV insertion point T1 time (a measure of myocardial fibrosis) and LV eccentricity or interventricular septal angle, measures of RV remodeling.<sup>29,30</sup> Similar to previous papers evaluating RV insertion point late gadolinium enhancement, Saunders et al. found no relationship between RV insertion point T1 time and outcomes.

Kawel-Boehm et al. examined T1 mapping of the RV free wall using standard modified look-locker inversion (an MRI sequence used for detecting myocardial fibrosis; MOLLI) recovery in 20 healthy controls.<sup>31</sup> The authors found that the average T1 time of the RV free wall was significantly longer than the left ventricle. The authors believed this was due to the naturally higher collagen content in the RV, but volume averaging

is also suspected. RV free wall T1 mapping was also evaluated in a recent study examining invasive pressure-volume loop measures in 42 patients with PH.<sup>32</sup> The authors found that RV free wall T1 time (when averaged with RV insertion point and interventricular septum T1 times) correlated significantly with end-diastolic stiffness but not RV-PA coupling.

Higher resolution T1 mapping sequences, which may be more appropriate for the thin-walled RV myocardium, have also been studied (Figure 3). Recently, an accelerated and respiratory navigator-gated look-locker imaging sequence (ANGIE) was developed for T1 quantification of the RV.<sup>33</sup> This technique provides higher spatial resolution for the thin-walled RV by using a segmented readout rather than a single-shot readout. The authors found that by using a midventricular short-axis slice during end systole at 1.5T, ANGIE provided similar RV T1 values to typical LV measurements in 9 healthy volunteers. In PH patients, ANGIE showed significantly increased RV diffuse fibrosis compared to subjects without PH, and this fibrosis was independently associated with PH even after adjustment for RV dilation and dysfunction.<sup>34</sup>





**Figure 3:** High resolution RV T1 mapping. Comparison of standard MRI technique (Standard-MOLLI) for T1 mapping to high-resolution MRI technique (HR-MOLLI) for T1 mapping. Note the better resolution of the RV free wall (white arrows). MOLLI = modified look-locker inversion recovery; RV = right ventricle.

#### *PA 4D Flow Imaging*

In conjunction with the development of novel MRI sequences to better understand the pathophysiology of the RV in PH, studies are also exploring additional methods such as 4D flow imaging to evaluate the pulmonary vasculature in this disease (Figure 4, see also Supplemental Clip 3). 4D flow MRI (time-resolved 3D phase-contrast MRI with 3-directional velocity encoding) offers the opportunity to noninvasively measure complex 3D hemodynamic changes with full volumetric coverage of the RV and PAs.<sup>35–37</sup> This technique provides both qualitative assessment of altered blood flow (such as helix and vortex formation) as well as quantitative hemodynamic measures such as wall shear stress, pulse wave velocity, and vorticity.

Using 4D flow MRI in the pulmonary circulation, Reiter et al. observed abnormal vortex development in the main PA in patients with both resting and exercise-induced pulmonary arterial hypertension (PAH).<sup>35</sup> Notably, the time persistence of this vortex correlated with the

degree of PH as measured by mean PA pressure. Barker et al. extended this finding by reporting a significant decrease in peak systolic velocity, peak flow, stroke volume, and wall shear stress in the main PA and both PA branches in patients with PAH compared to controls.<sup>38</sup> 4D flow imaging may also provide noninvasive assessment of more traditional hemodynamics. In PH patients with varying degrees of pulmonary vascular resistance by right heart catheterization, a multivariate regression equation that includes peak systolic vorticity, cardiac output, and relative area change in the main PA accurately estimated pulmonary vascular resistance across severe PH and normotensive populations.<sup>39</sup>

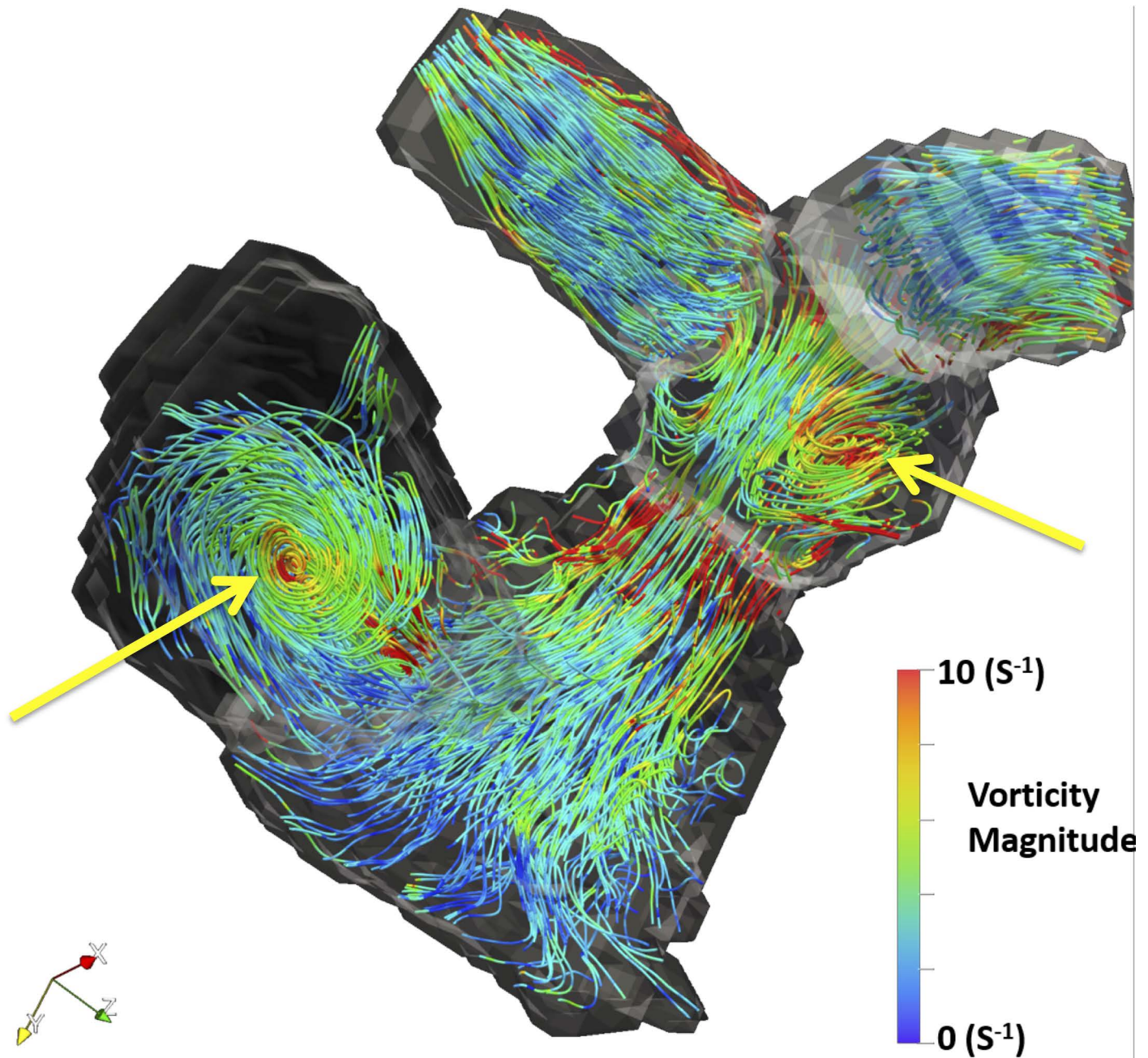
#### *Exercise MRI*

Recent progress in MRI-compatible exercise equipment makes it possible to evaluate the above novel sequences during stress conditions. Recreating the hemodynamic changes associated with exertion inside the MRI scanner provides unique insight into the pathophys-

ologic alterations within the RV and pulmonary vasculature that may permit earlier detection of the disease.

Several studies have focused on RV contractility during exercise and the ability of the RV to maintain an appropriate cardiac output despite increasing afterload. Using RVEF as a surrogate of RV contractile reserve, Jajjee et al. showed a decrease in RVEF with submaximal exercise in chronic PAH patients despite normal RV function at rest.<sup>40</sup> A separate study confirmed these findings and also showed that RV-PA coupling, as measured by stroke volume/end-systolic volume, was equally impaired with exercise in a small sample of patients with severe PAH.<sup>41</sup> In both studies, the key driver of poor RV contractility in patients with PAH was the inability to augment RV end-systolic volume during exercise.

In addition to standard cine images for measuring RVEF and volume, 2D-phase contrast imaging has been used to evaluate changes in PA stiffness during stress. In patients with PH, stiffness of the main PA was shown to sig-



**Figure 4:** 4-dimensional flow right heart and pulmonary arteries. Altered blood flow in a patient with pulmonary hypertension as measured by vorticity. Note the vortex in the right atrium and main pulmonary artery indicating altered blood flow (yellow arrows). Image courtesy of Mohammed Elbaz, PhD.

nificantly increase during exercise when measured by pulse wave velocity.<sup>42</sup> This change significantly correlated with the stiffness index,  $\beta$ , as measured by right heart catheterization. A recent study also evaluated the value and reproducibility of feature-tracking RV strain in PAH patients during exercise MRI. Similar to previous studies showing a decline in RVEF during stress, Lin et al. showed a significant impairment in RV longitudinal strain with exercise with minimal

inter-observer variability.<sup>43</sup> Changes in RV strain during exercise might be a more sensitive marker for RV contractility than changes in RVEF.

#### *Deep Learning*

The use of artificial intelligence for cardiovascular imaging is rapidly gaining momentum. There are currently several studies evaluating deep learning approaches for assessing cardiac chamber volume, mass, and EF. These automated

methods are particularly useful for MRI where manual biventricular segmentation is time-consuming and prone to errors. One recent study highlighted the benefit of adding anatomical shape prior knowledge to a 3D neural network-based segmentation method to specifically analyze biventricular size and function in patients with PH.<sup>44</sup> These refinements to existing deep learning approaches will likely be of significant value in future PH clinical trials.

## COMPUTED TOMOGRAPHY (CT) AND POSITRON EMISSION TOMOGRAPHY (PET)

Both CT and PET play a limited but potentially useful role in the evaluation of PH. Noncontrast CT is frequently used to evaluate the lung parenchyma and is necessary to diagnose PH due to lung disease. Noncontrast CT may also provide diagnostic clues for rare types of PH such as pulmonary veno-occlusive disease or pulmonary capillary hemangiomas. Dual-energy CT is a newer method that provides both functional and anatomical data of the pulmonary vasculature. This method has been tested in patients with chronic thromboembolic PH and has performed well in generating quantitative lung perfusion and angiography using a single acquisition.<sup>45</sup>

PET provides unique metabolic information in patients with PH, but its clinical role, due in part to cost, radiation, and lack of accessibility, has yet to be established. Several studies have shown increased myocardial and lung glucose utilization in patients with PH using <sup>18</sup>F-fluorodeoxyglucose (FDG).<sup>46,47</sup> The degree of FDG uptake significantly correlates with measures of RV dysfunction. FDG uptake also appears to predict outcomes in patients with PH and may be useful in tracking therapeutic efficacy.<sup>48,49</sup>

## CONCLUSION

As therapies continue to evolve for PH, emerging noninvasive imaging techniques will be crucial for the accurate assessment of cardiac structure, function, and blood flow. Noninvasive imaging modalities also offer tremendous potential as research tools to enhance our understanding of the pathophysiology of PH. Interdisciplinary teams including cardiology, radiology, and pulmonology should jointly be involved in the selection of one or more imaging tools to best manage these patients. Future PH studies should focus on the effectiveness of applying a value-based imaging approach centered on quality, safety, and cost.

## References

1. Bossone E, D'Andrea A, D'Alto M, et al. Echocardiography in pulmonary arterial hy-

pertension: from diagnosis to prognosis. *J Am Soc Echocardiogr.* 2013;26(1):1–14.

2. Cordina RL, Playford D, Lang I, Celermajer DS. State-of-the-art review: echocardiography in pulmonary hypertension. *Heart Lung Circ.* 2019;28(9):1351–1364.

3. Kossaify A. Echocardiographic assessment of the right ventricle, from the conventional approach to speckle tracking and three-dimensional imaging, and insights into the “right way” to explore the forgotten chamber. *Clin Med Insights Cardiol.* 2015;9:65–75.

4. Wright LM, Dwyer N, Celermajer D, Kritharides L, Marwick TH. Follow-up of pulmonary hypertension with echocardiography. *JACC Cardiovasc Imaging.* 2016;9(6):733–746.

5. Lang RM, Addetia K, Narang A, Mor-Avi V. 3-dimensional echocardiography: latest developments and future directions. *JACC Cardiovasc Imaging.* 2018;11(12):1854–1878.

6. Addetia K, Muraru D, Badano LP, Lang RM. New directions in right ventricular assessment using 3-dimensional echocardiography. *JAMA Cardiol.* 2019. doi:10.1001/jamacardio.2019.2424.

7. Leibundgut G, Rohner A, Grize L, et al. Dynamic assessment of right ventricular volumes and function by real-time three-dimensional echocardiography: a comparison study with magnetic resonance imaging in 100 adult patients. *J Am Soc Echocardiogr.* 2010;23(2):116–126.

8. Muraru D, Spadotto V, Cecchetto A, et al. New speckle-tracking algorithm for right ventricular volume analysis from three-dimensional echocardiographic data sets: validation with cardiac magnetic resonance and comparison with the previous analysis tool. *Eur Heart J Cardiovasc Imaging.* 2016;17(11):1279–1289.

9. Abouzeid CM, Shah T, Johri A, Weinsaft JW, Kim J. Multimodality imaging of the right ventricle. *Curr Treat Options Cardiovasc Med.* 2017;19(11):82.

10. Genovese D, Rashedi N, Weinert L, et al. Machine learning-based three-dimensional echocardiographic quantification of right ventricular size and function: validation against cardiac magnetic resonance. *J Am Soc Echocardiogr.* 2019;32(8):969–977.

11. Addetia K, Maffessanti F, Yamat M, et al. Three-dimensional echocardiography-based analysis of right ventricular shape in pulmonary arterial hypertension. *Eur Heart J Cardiovasc Imaging.* 2016;17(5):564–575.

12. Addetia K, Maffessanti F, Muraru D, et al. Morphologic analysis of the normal right ventricle using three-dimensional echocardiography-derived curvature indices. *J Am Soc Echocardiogr.* 2018;31(5):614–623.

13. Leary PJ, Kurtz CE, Hough CL, Waiss MP, Ralph DD, Sheehan FH. Three-dimensional analysis of right ventricular shape and function in pulmonary hypertension. *Pulm Circ.* 2012;2(1):34–40.

14. Medvedofsky D, Aronson D, Gomberg-Maitland M, et al. Tricuspid regurgitation progression and regression in pulmonary arterial

hypertension: implications for right ventricular and tricuspid valve apparatus geometry and patients outcome. *Eur Heart J Cardiovasc Imaging.* 2017;18(1):86–94.

15. Narang A, Addetia K. An introduction to left ventricular strain. *Curr Opin Cardiol.* 2018;33(5):455–463.

16. Fine NM, Chen L, Bastiansen PM, et al. Outcome prediction by quantitative right ventricular function assessment in 575 subjects evaluated for pulmonary hypertension. *Circ Cardiovasc Imaging.* 2013;6(5):711–721.

17. Sachdev A, Villarraga HR, Frantz RP, et al. Right ventricular strain for prediction of survival in patients with pulmonary arterial hypertension. *Chest.* 2011;139(6):1299–1309.

18. Borges AC, Knebel F, Eddicks S, et al. Right ventricular function assessed by two-dimensional strain and tissue Doppler echocardiography in patients with pulmonary arterial hypertension and effect of vasodilator therapy. *Am J Cardiol.* 2006;98(4):530–534.

19. Kishiki K, Singh A, Narang A, et al. Impact of severe pulmonary arterial hypertension on the left heart and prognostic implications. *J Am Soc Echocardiogr.* 2019;32(9):1128–1137.

20. Freed BH, Collins JD, François CJ, et al. MR and CT imaging for the evaluation of pulmonary hypertension. *JACC Cardiovasc Imaging.* 2016;9(6):715–732.

21. Hulshof HG, Eijssvogels TMH, Kleinnibelink G, et al. Prognostic value of right ventricular longitudinal strain in patients with pulmonary hypertension: a systematic review and meta-analysis. *Eur Heart J Cardiovasc Imaging.* 2019;20(4):475–484.

22. Wright L, Dwyer N, Wahi S, Marwick TH. Relative importance of baseline and longitudinal evaluation in the follow-up of vasodilator therapy in pulmonary arterial hypertension. *JACC Cardiovasc Imaging.* 2019;12(11 Pt 1):2103–2111.

23. Shehata ML, Harouni AA, Skrok J, et al. Regional and global biventricular function in pulmonary arterial hypertension: a cardiac MR imaging study. *Radiology.* 2013;266(1):114–122.

24. de Siqueira ME, Pozo E, Fernandes VR, et al. Characterization and clinical significance of right ventricular mechanics in pulmonary hypertension evaluated with cardiovascular magnetic resonance feature tracking. *J Cardiovasc Magn Reson.* 2016;18(1):39.

25. Tello K, Dalmer A, Vanderpool R, et al. Cardiac magnetic resonance imaging-based right ventricular strain analysis for assessment of coupling and diastolic function in pulmonary hypertension. *JACC Cardiovasc Imaging.* 2019;12(11 Pt 1):2155–2164.

26. Blyth KG, Groenning BA, Martin TN, et al. Contrast enhanced-cardiovascular magnetic resonance imaging in patients with pulmonary hypertension. *Eur Heart J.* 2005;26(19):1993–1999.

27. Freed BH, Gomberg-Maitland M, Chandra S, et al. Late gadolinium enhancement cardiovas-

- cular magnetic resonance predicts clinical worsening in patients with pulmonary hypertension. *J Cardiovasc Magn Reson*. 2012;14:11.
28. Swift AJ, Rajaram S, Capener D, et al. LGE patterns in pulmonary hypertension do not impact overall mortality. *JACC Cardiovasc Imaging*. 2014;7(12):1209–1217.
  29. Reiter U, Reiter G, Kovacs G, et al. Native myocardial T1 mapping in pulmonary hypertension: correlations with cardiac function and hemodynamics. *Eur Radiol*. 2017;27(1):157–166.
  30. Saunders LC, Johns CS, Stewart NJ, et al. Diagnostic and prognostic significance of cardiovascular magnetic resonance native myocardial T1 mapping in patients with pulmonary hypertension. *J Cardiovasc Magn Reson*. 2018;20(1):78.
  31. Kawel-Boehm N, Dellas Buser T, Greiser A, Bieri O, Bremerich J, Santini F. In-vivo assessment of normal T1 values of the right-ventricular myocardium by cardiac MRI. *Int J Cardiovasc Imaging*. 2014;30(2):323–328.
  32. Tello K, Dalmer A, Axmann J, et al. Reserve of right ventricular-arterial coupling in the setting of chronic overload. *Circ Heart Fail*. 2019;12(1):e005512.
  33. Mehta BB, Chen X, Bilchick KC, Salerno M, Epstein FH. Accelerated and navigator-gated look-locker imaging for cardiac T1 estimation (ANGIE): development and application to T1 mapping of the right ventricle. *Magn Reson Med*. 2015;73(1):150–160.
  34. Mehta BB, Auger DA, Gonzalez JA, et al. Detection of elevated right ventricular extracellular volume in pulmonary hypertension using Accelerated and Navigator-Gated Look-Locker Imaging for Cardiac T1 Estimation (ANGIE) cardiovascular magnetic resonance. *J Cardiovasc Magn Reson*. 2015;17:110.
  35. Reiter G, Reiter U, Kovacs G, et al. Magnetic resonance-derived 3-dimensional blood flow patterns in the main pulmonary artery as a marker of pulmonary hypertension and a measure of elevated mean pulmonary arterial pressure. *Circ Cardiovasc Imaging*. 2008;1(1):23–30.
  36. François CJ, Srinivasan S, Schiebler ML, et al. 4D cardiovascular magnetic resonance velocity mapping of alterations of right heart flow patterns and main pulmonary artery hemodynamics in tetralogy of Fallot. *J Cardiovasc Magn Reson*. 2012;14:16.
  37. Fredriksson AG, Zajac J, Eriksson J, et al. 4-D blood flow in the human right ventricle. *Am J Physiol Heart Circ Physiol*. 2011;301(6):H2344–H2350.
  38. Barker AJ, Roldán-Alzate A, Entezari P, et al. Four-dimensional flow assessment of pulmonary artery flow and wall shear stress in adult pulmonary arterial hypertension: results from two institutions. *Magn Reson Med*. 2015;73(5):1904–1913.
  39. Kheyfets VO, Schafer M, Podgorski CA, et al. 4D magnetic resonance flow imaging for estimating pulmonary vascular resistance in pulmonary hypertension. *J Magn Reson Imaging*. 2016;44(4):914–922.
  40. Jaijee S, Quinlan M, Tokarczuk P, et al. Exercise cardiac MRI unmasks right ventricular dysfunction in acute hypoxia and chronic pulmonary arterial hypertension. *Am J Physiol Heart Circ Physiol*. 2018;315(4):H950–H957.
  41. Lin AC, Strugnell WE, Seale H, et al. Exercise cardiac MRI-derived right ventriculo-arterial coupling ratio detects early right ventricular maladaptation in PAH. *Eur Respir J*. 2016;48(6):1797–1800.
  42. Forouzan O, Dinges E, Runo JR, et al. Exercise-induced changes in pulmonary artery stiffness in pulmonary hypertension. *Front Physiol*. 2019;10:269.
  43. Lin ACW, Seale H, Hamilton-Craig C, Morris NR, Strugnell W. Quantification of biventricular strain and assessment of ventriculo-ventricular interaction in pulmonary arterial hypertension using exercise cardiac magnetic resonance imaging and myocardial feature tracking. *J Magn Reson Imaging*. 2019;49(5):1427–1436.
  44. Duan J, Bello G, Schlemper J, et al. Automatic 3D bi-ventricular segmentation of cardiac images by a shape-refined multi-task deep learning approach. *IEEE Trans Med Imaging*. 2019;38(9):2151–2164.
  45. Dournes G, Verdier D, Montaudon M, et al. Dual-energy CT perfusion and angiography in chronic thromboembolic pulmonary hypertension: diagnostic accuracy and concordance with radionuclide scintigraphy. *Eur Radiol*. 2014;24(1):42–51.
  46. Wang L, Li W, Yang Y, et al. Quantitative assessment of right ventricular glucose metabolism in idiopathic pulmonary arterial hypertension patients: a longitudinal study. *Eur Heart J Cardiovasc Imaging*. 2016;17(10):1161–1168.
  47. Saygin D, Highland KB, Farha S, et al. Metabolic and functional evaluation of the heart and lungs in pulmonary hypertension by gated 2-[18F]-Fluoro-2-deoxy-D-glucose positron emission tomography. *Pulm Circ*. 2017;7(2):428–438.
  48. Tatebe S, Fukumoto Y, Oikawa-Wakayama M, et al. Enhanced [18F]fluorodeoxyglucose accumulation in the right ventricular free wall predicts long-term prognosis of patients with pulmonary hypertension: a preliminary observational study. *Eur Heart J Cardiovasc Imaging*. 2014;15(6):666–672.
  49. Oikawa M, Kagaya Y, Otani H, et al. Increased [18F]fluorodeoxyglucose accumulation in right ventricular free wall in patients with pulmonary hypertension and the effect of epoprostenol. *J Am Coll Cardiol*. 2005;45(11):1849–1855.

# The Present and Future of Imaging in Pulmonary Hypertension

This fall, Guest Editors Jeffrey D. Edelman, MD, Associate Professor of Medicine at the University of Washington in Seattle, and Harrison W. Farber, MD, Professor of Medicine at Tufts University School of Medicine in Boston, Massachusetts, convened a panel of experts to discuss the role of imaging in pulmonary hypertension. Guests included Benjamin H. Freed, MD, Assistant Professor of Medicine at Northwestern University Feinberg School of Medicine in Chicago, Illinois; Paul Hassoun, MD, Director of the Pulmonary Hypertension Program and Professor of Medicine at Johns Hopkins University Department of Medicine in Baltimore, Maryland; Peter Leary, MD, PhD, Associate Professor of Medicine and Director of the Pulmonary Vascular Disease Program at the University of Washington in Seattle; Sudhakar N.J. Pipavath, MD, Professor of Cardiothoracic Imaging and Adjunct Professor of Pulmonary, Critical Care, Sleep Medicine and Medicine at the University of Washington in Seattle; and Anjali Vaidya, MD, FACC, FASE, FACP, Associate Professor of Medicine and Co-Director, Pulmonary Hypertension, Right Heart Failure and CTEPH Program at Temple University in Philadelphia, Pennsylvania.

**Dr Edelman:** Good afternoon, everyone. Thanks for joining us. This is the roundtable for *Advances in Pulmonary Hypertension* Volume 18 issue 4, focusing on imaging in pulmonary hypertension (PH). I am Jeff Edelman, a pulmonologist at the University of Washington, and my co-moderator is Harrison Farber, a pulmonologist at Tufts University. Before we start, I was hoping we could go around and identify ourselves and our disciplines and where we are.

**Dr Pipavath:** Yes, I'm Sudhakar Pipavath, chest radiologist at the University of Washington, Seattle.

**Dr Hassoun:** Hi, this is Paul Hassoun, a pulmonologist at Johns Hopkins in Baltimore.

**Dr Vaidya:** This is Anjali Vaidya. I'm a cardiologist at Temple University.

**Dr Leary:** This is Peter Leary. I'm a pulmonologist at the University of Washington.

**Dr Freed:** I'm Ben Freed. I'm a cardiologist at Northwestern in Chicago.

**Dr Edelman:** Okay, excellent. Thank you. I'd like to start with the general comment that our imaging studies can play dual roles of identifying and finding patients with evidence of PH as well as in the evaluation of PH, such as assessing the severity and identifying

associated conditions. There is fundamental information that's assessed and identified on most studies in routine clinical settings, while more detailed data and evaluation can be obtained in more specialized settings. I think that experts from different fields, as we have in this group, bring different skillsets and perspectives to the table, and our overall evaluation is really enhanced by this multidisciplinary approach.

I hope our discussion today is going to reflect this diversity. I'm not sure where we're going to go in the next hour. I do have some basic starting points, but I think we'll let the discussion move from there. As a basic starting point, I think it's worthwhile to mention and discuss what imaging modalities we think are routine in evaluating patients with known or suspected PH.

**Dr Pipavath:** I look at imaging (radiology) of PH being useful in three areas. Number one is diagnosis of PH, be it early, or when there are clinical symptoms and signs. In this situation, one tends to employ an additional investigation and then try to make a diagnosis. The second area is to determine the cause of PH that we can figure out at imaging. There are various causes of PH that imaging can help identify. The third area is imaging as guidance for treatment in some conditions. We have not fully explored the ability of standard imaging in quantification, specifically assessment of severity of PH. I don't

think the standard imaging modalities are that great in terms of quantification.

Standard radiology imaging signs have certain predictive values for the diagnosis of PH. However, none of these are predictive enough to cross the treatment threshold for you to start treating PH on the basis of imaging signs alone.

You might employ an invasive study such as the right heart catheterization, which is considered the "gold standard." In practice, you may not be able to perform this test in everyone—this is my understanding, you all need to correct me if that's not the case—and that leads to the next best confirmatory test, the echocardiogram, where you are looking for a tricuspid regurgitation jet, I suppose. I'm sure the cardiologists will be able to say the most about its diagnostic value.

**Dr Edelman:** For the patient with symptoms that lead you to suspect PH, I think the basic imaging studies that we're going to start with are going to be chest x-ray, computed tomography (CT), echocardiogram, and ventilation-perfusion (V/Q) scan. There are some fundamental findings there that are going to further lead us down the PH pathway or perhaps identify some other cause of dyspnea. I think those are our basic workhorse studies. . . yes?

**Dr Vaidya:** I agree. I would just add, I think the question was along the lines of the routine imaging that's available

and used, and I think of it as echocardiogram, V/Q scan, and CT angiogram. Chest x-ray is important and can be helpful, but unfortunately, it's not utilized adequately to raise the suspicion diagnosis often enough. While we want to talk about it and teach about it, it's routinely not interpreted as abnormal in PH. The echocardiogram, of course, for basic awareness for PH, and then it has two additional utilities. One is to recognize the likelihood of the underlying hemodynamic profile that can then be confirmed by catheterization. The other utility is to use it as a guide once we're down the road of PH medical management to see if we've achieved treatment goals. Then the V/Q scan to make chronic thromboembolic PH (CTEPH) diagnosis, and then the CT is equally important to assess for underlying parenchymal lung disease, or if we're going to go down the road of CTEPH evaluations at Temple, to include the CT angiography. Those are my three.

**Dr Hassoun:** Are we talking about all imaging or just heart imaging? I'm a little bit confused there. Are we talking about all imaging in PH?

**Dr Edelman:** All imaging.

**Dr Hassoun:** I see. Okay.

**Dr Freed:** I would add to the discussion. I think that we also have to think about the judicious use of all these imaging modalities because we have a lot of them. We have CT and V/Q and chest x-rays and echocardiograms. We have to figure out a better way than sort of the shotgun approach to providing the information that's needed.

I think one of the big strengths of echocardiogram is that you can use it to not only identify PH, but to also help further refine where the PH might be coming from. There are many signs on echocardiogram that can help you differentiate between pulmonary arterial hypertension (PAH) or pulmonary venous hypertension. I think that can really help you figure out what potential other imaging modalities you might need, if anything else, before you go ahead and order all these other tests for the workup.

**Dr Farber:** Let me take that thought one step further. There's a paper from 3 or 4 years ago in which the authors, who were not clinicians, but just medical economists, looked at the workup for PH strictly from a monetary standpoint. They concluded that, on a cost-benefit ratio, the most cost-effective way to proceed if you think somebody has PH is, first, get an echocardiogram. If it's abnormal, proceed directly to right heart catheterization, and then do the rest of the workup if they have PAH because, with the prevalence of diastolic heart disease, you're going to do a lot of imaging or a lot of workup before you actually catheterize somebody who doesn't have the disease you're looking for.

**Dr Vaidya:** I completely agree. Either the echocardiogram has to strongly suggest a pulmonary vascular resistance (PVR) problem, or the right heart catheterization has to confirm a PVR problem before going down the full road of V/Q and CT of the chest.

**Dr Edelman:** There are nuances in both of those comments because I think Hap said, "if the echocardiogram suggests PAH," and then Anjali said, "specifically a PVR issue." If you were to take that further, the echocardiogram might be a stopping point, either if it was completely normal or if it suggested a left-sided cardiac problem. Am I interpreting those two comments correctly?

**Dr Vaidya:** Yes.

**Dr Pipavath:** The question that I have is, how often can you clinically suspect PH? Are there symptoms or clinical signs? Do they help you in any way, or are you mostly doing a study to assess the cause of shortness of breath, dyspnea, or dyspnea on exertion? Then you go through a series of investigations like just radiographs, CT, or echocardiogram. Then you arrive at the diagnosis of PH and then go downstream in terms of becoming more granular in workup?

**Dr Vaidya:** I think it can happen in a variety of ways. Both of those scenarios you described are quite common. There are going to be multiple providers out

there that are just simply working up dyspnea and ordering a host of imaging tests to work it up and then ultimately land on PH. Probably those of us in this conversation are accustomed to recognizing specific symptoms, things like exertion on presyncope, syncope, exertional angina, physical exam findings that are very obvious to us for right heart congestion, the right heart abnormalities. We may go down that route in a more focused way earlier, but I think it can happen either way.

**Dr Farber:** Also, nowadays, realistically, people who are short of breath usually get an echocardiogram fairly early and/or a chest x-ray. If the chest x-ray is at all suggestive, you get an echocardiogram. If that is abnormal, go directly to catheterization.

**Dr Pipavath:** This might be a stupid question, but whenever you do an echocardiogram, do you always look for the pulmonary artery pressures?

**Dr Farber:** Sure. However, I am more interested in what the right ventricle looks like. The only question with the echocardiogram is, do you do tricuspid annular plane systolic excursions (TAPSE) on everybody, right ventricular outflow tract (RVOT), pulmonary artery acceleration time, etc.? The cardiologists can play with that.

**Dr Pipavath:** What is the sensitivity of echocardiogram? Does it pick up all cases of PAH?

**Dr Farber:** The false-positive rate was said to be 30% to 40%. That may be a little better now. The false-negative rate is unknown; it's thought to be very low, but nobody actually knows the number because you don't catheterize a whole bunch of people with normal echocardiograms.

**Dr Leary:** I would like to double back on the false-negative rate of echocardiography. There is a tendency to focus just on the estimates of right ventricular (RV) systolic pressure on the echocardiogram, but when you narrow in on the pressure, you lose a lot of the richness in

the echocardiogram in order to inform the diagnosis. Once you take into account RV dilation, RV dysfunction, and notching of the RV outflow tract Doppler envelope, then even if the RV systolic pressure does not suggest that you have PH, the sensitivity of echocardiogram to pick up meaningful pulmonary vascular disease goes up. When you rely on just pressures alone, you are certainly going to miss some people.

**Dr Freed:** I couldn't agree more. It's not just about the pulmonary arterial pressure, which we do get on all patients, but you're also looking for septal flattening, RV function, and then some of the things I mentioned in terms of trying to differentiate between left-sided causes of PH versus more a precapillary process. Echocardiogram is very rich, if you use it properly, in providing a lot of information that can really help your diagnosis and determining whether or not this patient truly has PH.

**Dr Vaidya:** You could go so far as to say that the RV systolic pressure estimation or the pulmonary artery systolic pressure estimation is the least helpful part of an echocardiogram outside of the initial screening and recognition that there's an underlying problem. Everything else is so much more useful in terms of the left atrial size, the E/e' ratio, the systolic septal flattening, or the pulse wave Doppler in the RVOT, as well as the RV size and function. When you put all that together, I completely agree with what was said, that it is very rich and full of information. The pressure estimation alone has the least utility.

**Dr Pipavath:** Would you say then that there is no requirement for right heart catheterization because false negativity is pretty close to zero? I'm obviously asking a leading question.

**Dr Vaidya:** No. I don't think you can say that there is no role for the right heart catheterization; there will also be too many users without adequate expertise making mistakes on this basis. The utility is to recognize early on what the likely underlying hemodynamic profile is and then move quickly to confirm that

and move quickly to do the subsequent testing, like Hap said earlier. Get the V/Q. Get the additional chest imaging if it's suggestive of that. Move more quickly to the right heart catheterization when you have features that suggest an underlying PVR problem versus maybe looking more closely for risk factors for left heart congestion when you have the other appearance on the echocardiogram, but the catheterization should still be done. It should be done with a little more insight.

**Dr Edelman:** In the sixth World Symposium consensus proceedings section addressing PH due to left heart disease, there's actually a nice table that combines echocardiogram and other clinical findings to characterize the pretest probability of left heart disease phenotype. So using echocardiogram findings and other clinical data, one can define scenarios where maybe all you need is the echocardiogram to say there's probably not PH here, or there is PH, but it is very likely due to a left-sided etiology. I think that combination of study findings with clinical suspicion is certainly important in guiding decisions as well.

**Dr Leary:** I think that it was important how you framed this as a negative, Jeff, and I agree. Echocardiogram is relatively good at excluding a diagnosis of PAH either by arguing against PH altogether or by arguing for left heart disease as the explanation for PH. On the other hand, even if an echocardiogram looks like PAH, it is not adequate to confirm a diagnosis of PAH. Even if you don't see clear evidence of left ventricular systolic dysfunction or valvular cardiomyopathy, if you're playing the numbers, it is still probably more likely to represent heart failure with preserved ejection fraction than PAH. For me, this is still the key reason why right heart catheterization really can't leave our algorithm. If we neglected the heart catheterization, we would likely be mistreating a phenomenal number of people who really have diastolic dysfunction that was difficult to appreciate or misinterpreted on the echocardiogram.

**Dr Edelman:** I agree with that, Peter. I guess I was framing it in the setting

where you may have enough information to determine that there is a likely PH etiology, such as left-sided heart disease, for which you might proceed to treatment without right heart catheterization. I wasn't saying that, if you suspect that there's PAH, the echocardiogram is good enough, but that there are settings where you can, with good reliability, identify an etiology and direct therapy for the etiology without the heart catheterization.

**Dr Vaidya:** I agree with that. There's another angle of this, too, where we are so commonly discussing how right heart catheterization is the "gold standard" in the diagnosis of PH. That's only the case if it's done accurately. The flip side is how commonly patients with true PAH or CTEPH or a predominantly PVR lesion have an underoccluded technical error when trying to get an accurate wedge pressure. It's because their distal pulmonary arteries are larger in caliber, and this is a very common technical error that leads to an overestimated wedge pressure and missing the accurate diagnosis of PAH. It's part of why it still takes 2 ½ years to make an accurate diagnosis.

That error can be vastly avoided if we are properly interpreting the echocardiogram in advance. Our fellows, for example, know that they are not to scrub in on a right heart catheterization with us until they've looked at the echocardiogram images themselves, so that if they underocclude a pulmonary capillary wedge tracing and the tracing blunts and it looks like it could be a venous wedge waveform but it's 28 mm Hg when the patient echocardiogram has severe septal flattening, an E/e' of 7, a small left artery, and an RVOT notch, then they know that they've probably underoccluded, and they have to pay more careful attention technically in the catheterization lab.

The echocardiogram can be very helpful both ways to ensure that the right heart catheterization is also providing hemodynamic data that's most consistent with the patient's true overall clinical presentation.

**Dr Edelman:** All echocardiograms are not alike. All right heart catheterizations

are not alike. When you get information that doesn't fit, sometimes you need to step back and look at where the potential for error is. Some of these studies are being done at centers with different focuses or experience. PH centers can play a role in integrating and further reviewing the quality as well as obtaining more nuanced information from these studies.

**Dr Farber:** Just one last point about all that: the other part of this is that the echocardiogram is not near 100% accurate in diagnosing or suggesting diastolic heart disease. That's one issue; the second aspect is that there are people who have every risk factor for diastolic heart disease and have true precapillary PAH. So I don't know how, at least currently, you're going to get away from right heart catheterizations, nor should you.

**Dr Hassoun:** I'll say something about our experience, which is quite skewed at Hopkins, because we're a PH center, and patients come in with a suspicion of PH. They've had sometimes several echocardiograms or other tests. We always start with the chest x-ray, V/Q scan, and CT scan with pulmonary angiogram (CTPA) to exclude either lung disease or thromboembolic disease. V/Q scan is a must for all our patients.

I agree with all that's been said about echocardiograms in terms of the usefulness in ruling out valvular disease, diastolic dysfunction, left heart disease, etc. It's extremely helpful. I agree with the comments made by Anjali about the RV systolic pressure, and this is the thing that I pay least attention to. I look at RV morphology, volume, septal displacement. We do TAPSE on all our patients, not only to assess RV proper function, but also for risk stratification.

We also use TAPSE for follow up. We decide based on the echocardiogram whether it's left heart disease or more likely right heart disease, and that will lead us to eventually do a cardiac catheterization. To give you an example, if I have a middle-aged obese patient who has some systemic hypertension, an RV systolic pressure of 50, but a normal RV volume, I would be tempted to get a sleep study first and treat for 6 months

in case a sleep disorder is confirmed before repeating the echocardiogram and deciding on further action.

We eventually perform right heart catheterization on all patients with a PH suspicion. This comes after a set of baseline tests that will lead us to place the patient in 1 of the 5 groups of World Symposium on Pulmonary Hypertension (WSPH) classification of PH. I am saying our experience is skewed because these patients come in with a suspected diagnosis of PH, and the challenge then becomes to decide whether this patient fits mainly in Group 1, Group 2, Group 3, Group 4, or Group 5. This will be very important before doing a right heart catheterization and considering treatment.

In addition, we use the echocardiogram for risk stratification, and if you look at the REVEAL score or the European Society of Cardiology/European Respiratory Society (ESC/ERS) recommendations, unfortunately, there is only pericardial effusion considered in the REVEAL score, and pericardial effusion and right arterial area for the so-called ESC/ERS traffic light table. I think more echocardiogram findings like TAPSE, fractional area change, or degree of tricuspid regurgitation should be used for stratification.

Finally, we use the echocardiogram for follow up after initiation of treatment, mainly focusing on TAPSE, fractional area change, to see if there are changes of function of the RV chamber. We haven't talked about cardiac magnetic resonance imaging (MRI). We do cardiac MRI mainly for research purposes, but this is a modality that can be extremely important, at least for PAH in terms of assessing, again, RV function, such as RV ejection fraction, which has been shown to correlate with survival. There are so many other useful parameters that you can get with cardiac MRI.

**Dr Vaidya:** I would agree with that comment regarding the guidelines table. I've always thought it's unfortunate that they only include right atrial area and pericardial effusion because that is a little limiting in broad utility, and there are data to support TAPSE and fractional area change and other features.

I think of it as overall echo markers of right heart performance. I completely agree that pericardial effusion and right atrial area should not be the only things included in that category.

**Dr Leary:** I don't disagree with either of those comments, but from a logistical standpoint, what I think that the existing risk scores show us is that where we are right now in PH, we certainly don't have a single magical imaging variable that prognosticates for our patients. So we're left with old-school scales of justice, where we stack data on one side or the other to try and get a sense of whether our patient really is in a low-, intermediate-, or high-risk category. I think that we can broadly agree that imaging markers of the RV, whatever your favorite may be, are an important part of that risk assessment. The degree of derangement in a single marker may outweigh votes in a bunch of other categories, but any given marker rarely stands alone. What I heard from Paul and Anjali is that we have a lot of good markers out there. People have done good work correlating these to disease progression. What can be challenging with the plethora of high-dimensional data is deciding how to weight these things in clinical practice and coming up with a framework to put that into.

I don't envy the people who created the risk scores for that reason. . . to try and make something that's manageable, incorporating all these various inputs, all of which are somewhat colinear and hopefully are telling you similar things. Ultimately, though, I still think that you do want to look holistically at this and not get too married to any individual marker.

**Dr Hassoun:** I agree with you, Peter. I was complaining about the fact that, whether the REVEAL or the ESC/ERS risk scores, they have a couple of elements of echocardiograms. There are many biomarkers that have been associated with survival. I agree with you that we need to have a more holistic approach. If you look at the work that was done in the Swedish, in the German, and in the French registries using



the ESC/ERS risk stratification, they've looked at between 4 and 8 variables: hemodynamics, a little bit of echocardiogram, function, hemodynamics, etc. I think we need to have a number of imaging parameters to incorporate into our stratification scores.

MRI is not even mentioned in any of these. I think obtaining MRI may be more complicated from an availability standpoint, but I think it gives you so much more accurate information on both the left and the right heart and coupling between the right ventricle and the pulmonary artery and so many other things such as myocardial perfusion reserve by cardiac MRI, which we find correlates with survival. That means that there are so many things that have not been explored from an imaging standpoint.

**Dr Edelman:** I think we should talk about the role and potential role of MRI. I want to save that for just a little bit later. I'm still sticking to routine tests. I want to come back and talk a little bit about CT and V/Q scanning and their current roles and limitations because I think that, a lot of times, we are seeing patients who come in with dyspnea and often one of the first tests that's ordered is a CT, particularly CT angiogram, to look for acute pulmonary embolism. On many of these studies, there's no pulmonary embolism, but there are findings of PH such as pulmonary artery enlargement.

There is a lot of information that often isn't looked at. You can get fairly good assessments of some of the cardiac structures as well and get some further ideas as to what may be contributing if there is PH present, including information regarding underlying lung disease.

**Dr Leary:** As with any imaging test, I think it's hugely important where it's being used. There is a ton of information on a CT scan, and I'm going to focus in on CTEPH for a second. If you put a CTPA in the hands of a chest radiologist, particularly one who's focused on CTEPH or at a CTEPH center—even without a V/Q scan, they reliably identify the features of CTEPH that make the diagnosis likely based on the CT alone.

In this scenario, I think CTPA really does tell you a ton.

On the other hand, we also know that CT reads from someone who is not focused on CTEPH can frequently miss the features of the disease on CT. In this context, something like a V/Q scan is necessary to really draw attention to the perfusion fall out. I don't think that we have moved beyond the era of V/Q scanning PH patients, mostly because of these differences in expertise or focus in terms of who's reading the scan. While the technology is sound, I think greater expertise and focus than is widely available is necessary to really pull out a lot of the features that are important on a CTPA as they relate to PH in routine practice.

**Dr Edelman:** Peter, just like you said before about echocardiogram, I think the point is that there's a richness, to use your words, in CT imaging as well that isn't always readily tapped into at every location.

**Dr Leary:** Yes, that sounds right.

**Dr Vaidya:** I agree completely with the comments about CTPA and its use in CTEPH. That is certainly our experience at Temple, where the outside scans are sometimes not recognizing the findings that are truly, clinically obvious in our interpretations, but what a difference it makes, based on a center's volume and experience in recognizing the disease state. I agree that the V/Q needs to remain part of the algorithm for the general clinician workup out there.

**Dr Freed:** I agree, too, that the V/Q needs to remain part of the algorithm. I think there are technological changes coming down the pipeline with CT, like dual-energy CT, that might be able to help in giving both anatomical and perfusion information. It's not there yet, and it's certainly not ubiquitous by any stretch, but I think that, as technology improves, we might be able to get our information out of one imaging modality rather than multiple ones, but certainly in total agreement that V/Q scan is still a major part of this workup.

**Dr Pipavath:** I don't do nuclear medicine, so do you typically use V/Q scan as a rule-in modality or a rule-out modality? You are probably not, just on the basis of perfusion defects alone, suggesting CTEPH and starting to treat it. You would require a morphologic correlate, wouldn't you say that?

**Dr Vaidya:** Correct.

**Dr Pipavath:** You will move onto CT angiogram in someone who has a slightly higher pretest probability at that point and then look more carefully to make sure that there is or there is no physical occlusion or a linear filling defect or a peripheral filling defect indicating CTEPH.

**Dr Vaidya:** That's correct. The V/Q scan is very sensitive, but not specific, and so the CT angiogram is critical to then rule out other mimickers of CTEPH and to further characterize the location and nature of thromboembolic disease.

**Dr Pipavath:** What do you do when the V/Q scan is positive but there is no physical correlate? Do you just assume that it is because of Group 1 disease by excluding everything else?

**Dr Vaidya:** It can be that the description of a V/Q scan being positive in that context needs to again be interpreted by a CTEPH center because sometimes even the interpretation of the V/Q scans can be more complex than realized, and they can be read as false positive sometimes as well.

**Dr Freed:** Yes, and then there are diseases like sarcoma or vasculitis or pulmonary veno-occlusive disease or fibrosing mediastinitis. All of those can be false positives on a V/Q scan.

**Dr Edelman:** I think the value of the V/Q scan in this assessment, as Anjali said before, is really more of its negative predictive value. That really takes CTEPH off your list, and that's why it stays in the algorithm. It's readily available. It's got very defined interpretation guidelines as opposed to what we heard about CT, where CT at the right place,

in the right hands, read by the right person, may approach that kind of operating characteristic of  $V/Q$ , but I had to add a lot of caveats to get there.

**Dr Leary:** I said that CT was rich, and I don't back away from that statement. That's not to say that I think we've climbed the mountain and are at the top. I think that, particularly as we've delved further and further into balloon pulmonary angioplasty and are working on chronic total occlusions and distal disease, what we're finding is that we're bumping into the limitations of a CTPA to really define anatomical disease in a way that's as good as we want it to be, as we start targeting smaller vessels and taking different approaches to treat the disease.

Maybe dual-energy or some of these other approaches will get us there. Maybe they won't, but I think there is still room for improvement in imaging around this space.

**Dr Farber:** To summarize, part of the problem is there are none of these imaging techniques that are specific enough to avoid any of the others. If you're going to evaluate somebody for CTEPH, there are multiple different imaging techniques that are used so the surgeons or those doing balloon pulmonary angioplasty have an idea of what they will encounter.

**Dr Edelman:** I think we should probably spend some time discussing studies that are perhaps not as routinely used, such as cardiac MRI in evaluating PH.

**Dr Freed:** I think this was mentioned earlier, but one of the bread-and-butter kinds of things that MRI does is give you accurate RV volumes, RV ejection fraction, and RV mass. You don't need contrast for it, it doesn't take long to get it, and there's no radiation involved. That alone, just giving you that type of information, is huge and really overcomes the limitations of echocardiography because it's a 3-dimensional imaging modality. You can get a more global assessment of RV function, and this is what really helps to prognosticate in these patients.

That's just the basic stuff that MRI can do, not to mention all the other sequences like tissue characterization that could potentially be helpful.

**Dr Leary:** As a physiologist and somebody who enjoys the idea of thinking about the RV an awful lot, I love MRI. Despite that fact, I use MRI almost not at all in my clinical practice outside of our research studies.

Within the setting of a multipronged risk stratification approach where we're looking at B-type natriuretic peptide and 6-minute walk and some form of RV imaging, I've yet to be convinced that clinically a cardiac MRI has risen to that level where the juice is worth the squeeze, so to speak. Our patients tend to like echocardiography better; it is more accessible and is less costly to the system. I am just not sure that, in a multipronged risk stratification approach, use of cardiac MRI over echocardiogram moves the needle on prognostication. I love it as somebody who likes thinking about the RV, but I will say that clinically I don't actually use it all that much.

**Dr Pipavath:** What do you think are its limitations? I don't do cardiac MRI. My colleagues do it here. Those who do cardiac MRI, they seem to claim that it is, as you said, much more reproducible, but what—is it just the expense and the patient going into the magnet? Some of my colleagues have said that the expense tends to be very similar sometimes, but obviously the mean might be different at different locations. Is it just the expense, or is it that enough data have not been produced to comment on it?

**Dr Leary:** I'd say, for us, partially it's the expense and partially just my bias. At least our long-term patients have grown up on echocardiograms, and so MRI feels intimidating. We've had a lot more pushback from patients after they get their MRI than after they get their echocardiogram. That's just anecdotal experience, but it is fairly consistent anecdotal experience.

**Dr Freed:** I completely appreciate what you're saying. I think that problems come when you're at a center where potentially

the echocardiograms are not read correctly, as we talked about before, or you simply have a lot of difficulty seeing the right ventricle for a variety of reasons. I think that's when MRI might be particularly useful. I certainly don't use it for every patient either, but there are still a number of cases where it could be helpful. I think this is also why, in the world of MRI, there's a push to try to find other indications for MRI in this patient population that will make it worthwhile to go ahead and get that test, things that MRI can provide that echocardiography can't and are useful in the management of these patients. I don't know if we're quite there yet, but there are a number of techniques being studied for this reason.

**Dr Edelman:** Can you elaborate on that a little more? I think your article in this issue talks quite a bit about RV strain.

**Dr Freed:** Yes. We talk about RV strain both for echocardiography and MRI. There's a lot of literature out there on using RV strain with MRI, in a relatively easy way with no special sequence that you need to use ahead of time. In addition, there is 4-dimensional flow and T1 mapping, which provide data on flow dynamics and diffuse fibrosis, respectively. I think it's still in its infancy in terms of what we can use it for in PH. There are studies out there showing that identifying diffuse fibrosis either in the septum or potentially in the RV free wall can be helpful in figuring out prognosis, for instance.

**Dr Edelman:** Another information source that may lead to PH identification are MRIs that might be obtained for evaluation of left ventricular issues and then come back with findings that then trigger a PH evaluation.

**Dr Freed:** Yes. MRIs can provide information similar to echocardiograms in terms of helping you with where exactly the PH is coming from, but it probably goes beyond echocardiography, too. For instance, MRI can help identify both intra- and extracardiac shunts, which 2-dimensional echocardiography might not be able to visualize. I agree MRI can also help in differentiating the

mechanisms or where the PH is actually coming from.

**Dr Edelman:** We're getting close to the end of our hour here. I think we've covered most of what we had hoped to cover, but also want to give the opportunity for general comments or other things that people feel we may have missed and would like to add in here.

**Dr Leary:** We haven't even talked about positron emission tomography! I must say, it's a cool idea. As we move forward in im-

aging, thinking about trying to understand stress at the cellular level is an idea that's out there and has some data behind it. It is certainly not ready for primetime clinically, but I think that, at the end of the day, we are trying to understand the myocyte under stress in the setting of increased afterload. I think we use morphology and strain and function as surrogates of that cellular stress, and I wonder if, in the future, we'll be looking at biomarkers that are more focused in on the myocyte under strain. It's kind of pie-in-the-sky stuff, but interesting to think about.

**Dr Edelman:** There is great potential for these studies to enhance our understanding of disease pathophysiology as well. I think that's really where we would be going with MRI and positron emission tomography and studies that aren't currently routinely used in clinical PH evaluation.

I think we have reached the end of our hour, and I want to thank everyone for your input and participation. It's been a great discussion.

# Radiographic Signs and Patterns of Pulmonary Hypertension: A Pictorial Essay

*Section Editor*

Sean M. Studer, MD, MSc, FCCP

Hugo Carmona, MD  
*Department of Medicine  
 University of Washington  
 Seattle, WA*

Wei Wu, MD  
*Department of Radiology  
 University of Washington  
 Seattle, WA*

Sudhakar N.J. Pipavath, MD  
*Department of Radiology  
 University of Washington  
 Seattle, WA*

## INTRODUCTION

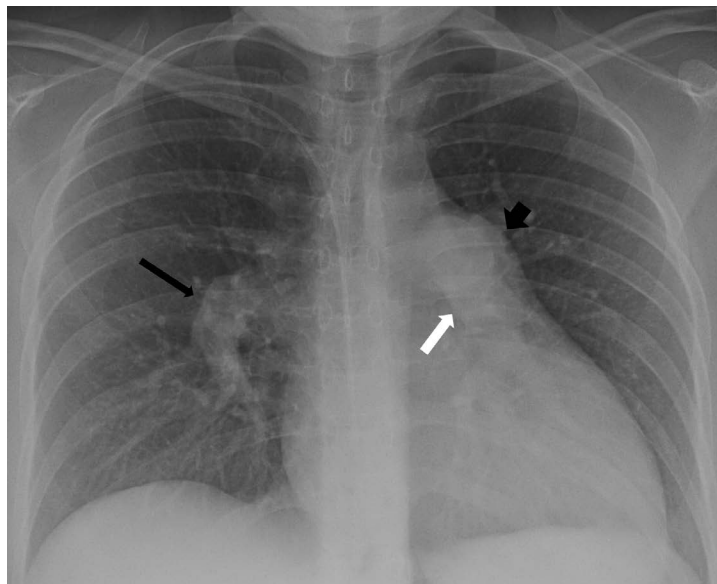
Pulmonary hypertension (PH) is a disease characterized by elevated mean pulmonary arterial pressure and/or elevated pulmonary vascular resistance, as measured by right heart catheterization.<sup>1-4</sup> Individuals often present with dyspnea and decreased functional exertion. Imaging features of PH may be present prior to clinical diagnosis. Certain radiographic signs can be useful in identifying the etiology of the PH.<sup>5</sup> We

present a variety of imaging features that are aimed at making these etiologies apparent to clinicians, with a focus on those etiologies that do not otherwise usually have distinguishing clinical manifestations.

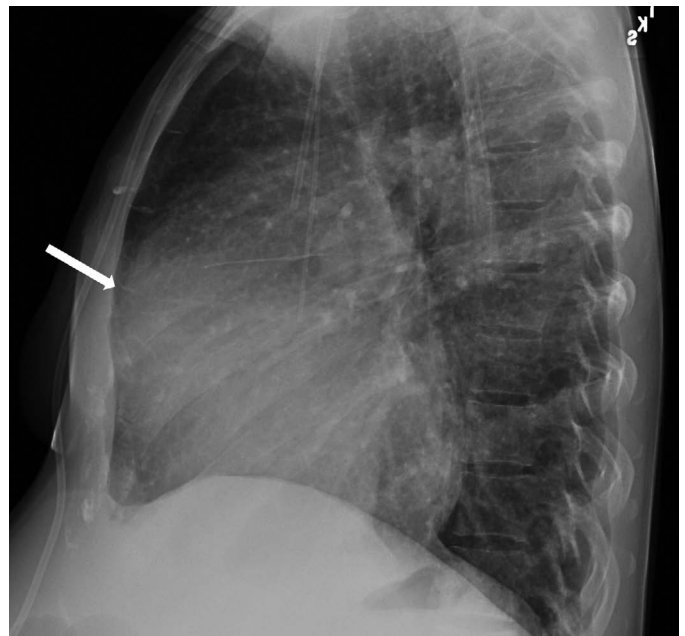
## EVIDENCE OF PH ON PLAIN CHEST RADIOGRAPHY

There are a variety of signs that are present in advanced PH regardless of etiology. The most obvious begin with

the changes in the main pulmonary artery (PA) itself. On plain radiography, enlargement of the main PA typically obscures the expected concavity between the aortic arch and the main PA silhouette, the so-called “aortopulmonary window” (Figure 1). Additionally, dilated descending left and right PAs can suggest PH (Figures 2 and 3). Right atrial enlargement and right ventricle (RV) enlargement (Figure 2) may also be evident.



**Figure 1:** Frontal chest radiograph of a 25-year-old woman with Group 1 pulmonary arterial hypertension secondary to systemic lupus erythematosus demonstrating loss of the aortopulmonary window (thick black arrow), now replaced by an outward convexity, due to main pulmonary artery enlargement. Additionally, the individual has bilateral dilated descending pulmonary arteries (thin black arrow [right] and white arrow [left]).

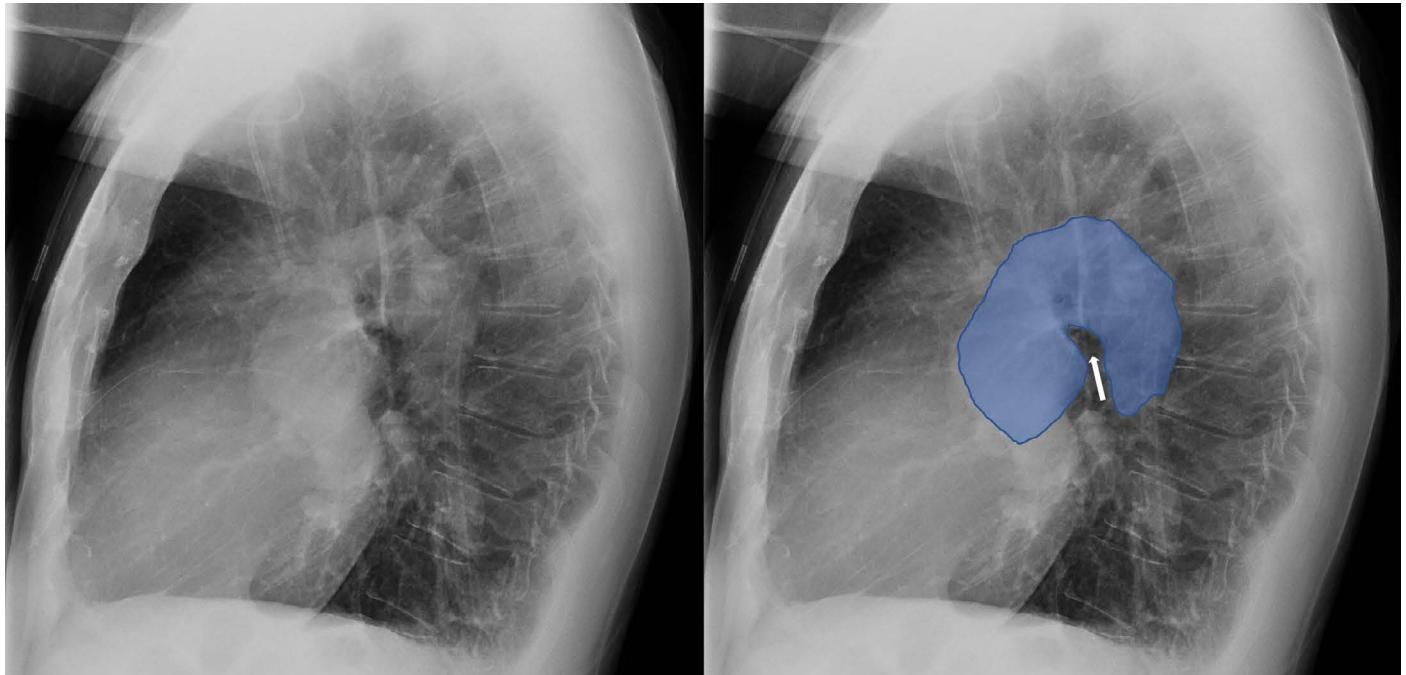


**Figure 2:** Lateral chest radiograph of a 33-year-old woman with pulmonary arterial hypertension and plexogenic arteriopathy demonstrates right ventricular enlargement as evidenced by obscuration of the expected retrosternal clear space (white arrow).

**Key Words**—pulmonary hypertension, pulmonary arterial hypertension, radiographic signs, CT signs

Correspondence: hcarmona@uw.edu

Disclosure: The authors have no relevant personal financial relationships to disclose.



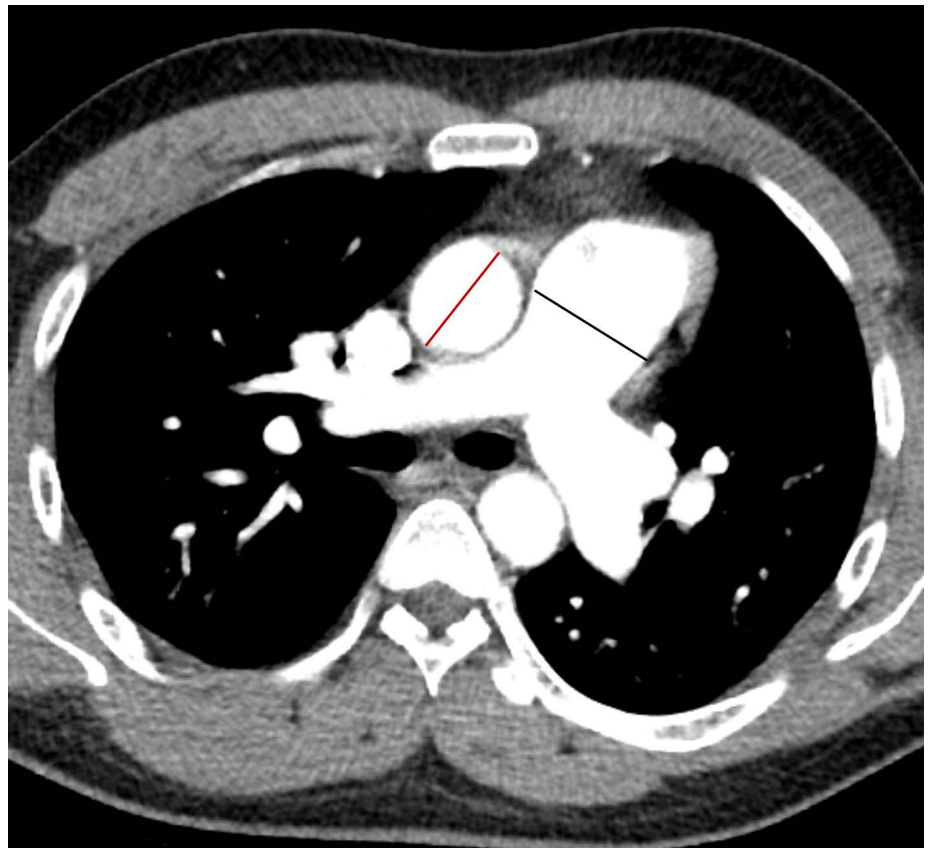
**Figure 3:** Lateral chest radiograph of a 46-year-old man with idiopathic pulmonary arterial hypertension demonstrating enlargement of the pulmonary arteries (PAs; blue) around the left main stem bronchus (arrow). The end-on appearing left mainstem bronchus is bordered by the aorta posteriorly and superiorly and the PAs anteriorly. These enlarged PAs have been described as an “incomplete donut” sign.

### EVIDENCE OF PH ON CT

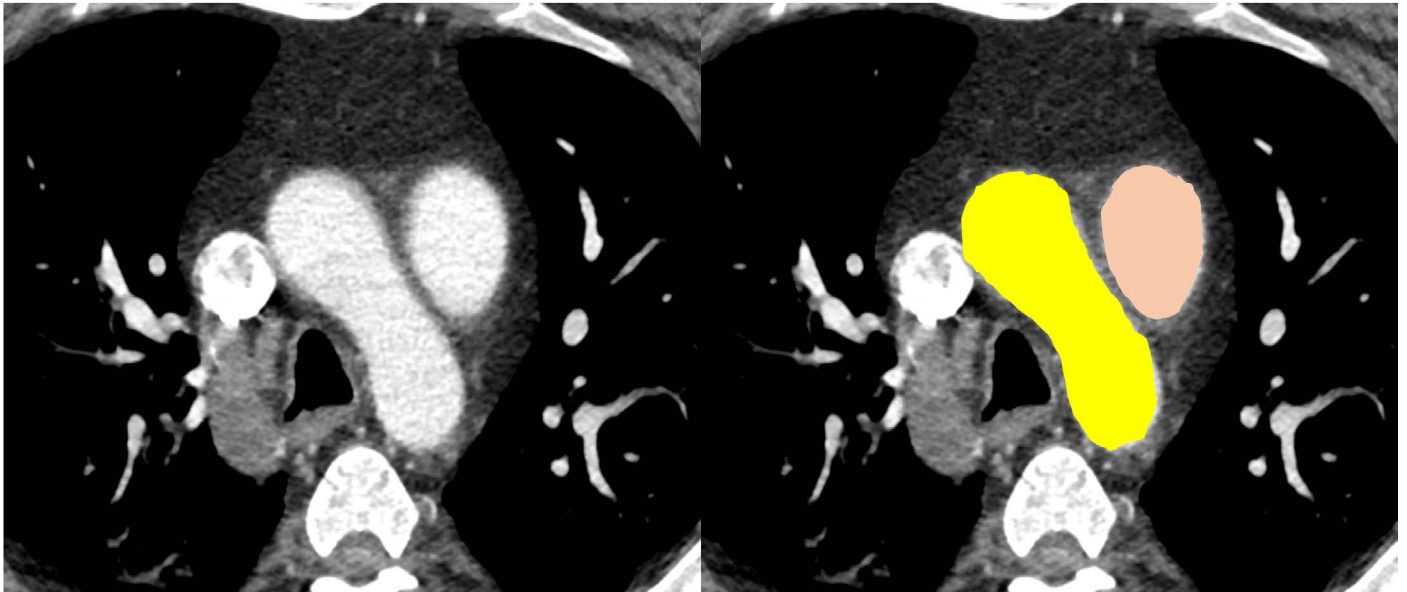
The main PA diameter (mPAD) should be measured on computed tomography (CT) 1 cm from the bifurcation of the right and left PAs, or at least at the widest portion within 3 cm of the bifurcation<sup>6</sup> (Figure 4). An mPAD  $\geq 29$  mm has a sensitivity of 87%, specificity of 89%, and positive predictive value (PPV) of 0.97 for PH.<sup>6</sup> Another common measurement compares mPAD to aorta diameter, abbreviated here as PA-Ao ratio. A PA-Ao ratio  $>1$  has a sensitivity of 57% and a specificity of 81% for PH.<sup>7</sup> While mPAD dilation can suggest the presence of PH, it does not correlate with PH severity, but rather to the length of time that PH has been present.<sup>8</sup>

In addition to static measurements of the great vessels, Scelsi et al.<sup>7</sup> have shown that being able to visualize the main PA at the same level as the most caudal aspect of the aortic arch, the so called “egg-and-banana” sign (Figure 5), is also associated with the presence of PH. Particularly, they noted that its presence had a similar PPV (85%) to the PA-Ao ratio  $>1$  (PPV 87%) and that the combination increased the PPV to 90%.

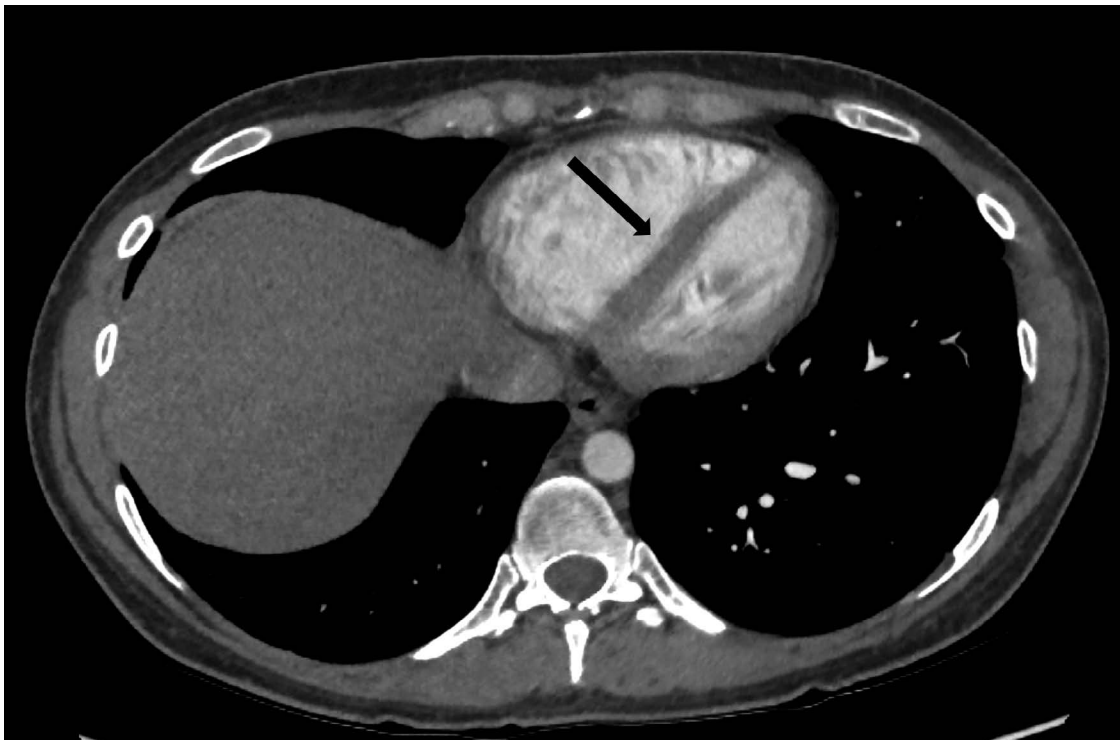Left ventricle (LV) and RV characteristics can also point to the presence of PH (Figure 6). An RV free wall thick-



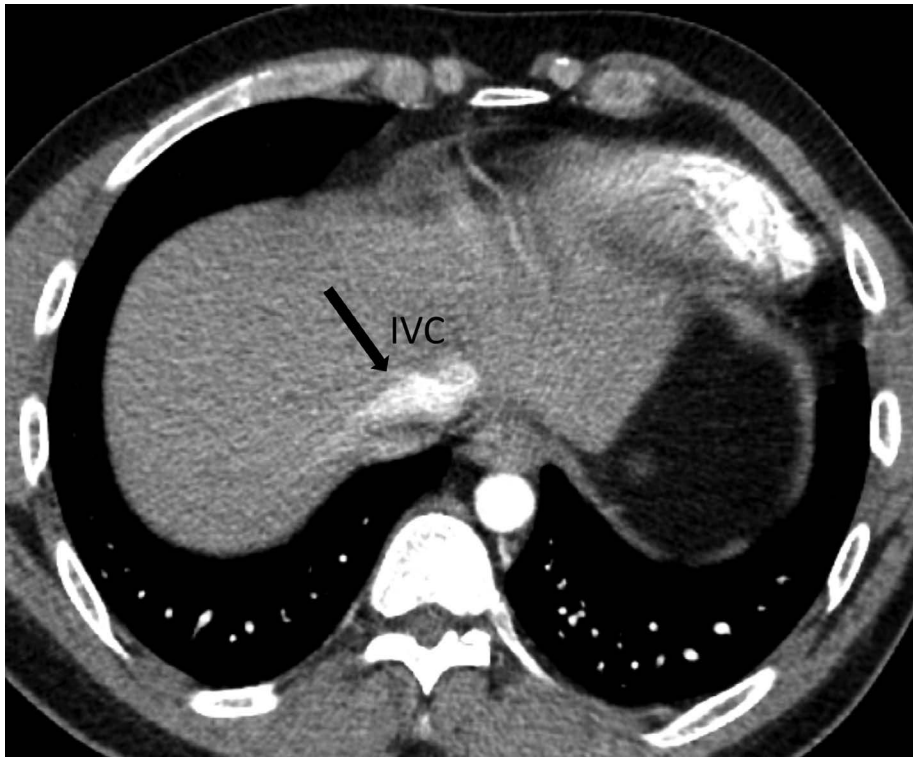
**Figure 4:** Computed tomographic angiogram in a 37-year-old man with pulmonary hypertension (PH) demonstrating maximum diameter of the ascending aorta (red line, 31 mm) and main pulmonary artery diameter (black line, 35 mm). Here, the pulmonary artery-to-aorta ratio is 1.16. A ratio  $>1$  has a sensitivity of 57% and specificity of 81% for PH.



**Figure 5:** Computed tomographic angiogram of the chest at the level of the caudal aspect of the aortic arch (yellow) in a 32-year-old man with Wiskott-Aldrich syndrome complicated with pulmonary hypertension. Note that the main pulmonary artery (pink) is visible at this level, the so called “egg-and-banana” sign.



**Figure 6:** Computed tomography of the chest with contrast, demonstrating an increased right ventricle-to-left ventricle ratio, as well as interventricular septal flattening (black arrow) in an individual with pulmonary hypertension, suggesting right ventricular pressure overload.



**Figure 7:** Computed tomographic angiogram of the chest demonstrating reflux at the level of the inferior vena cava (IVC; black arrow) due to elevated pulmonary artery pressures and elevated pulmonary vascular resistance.

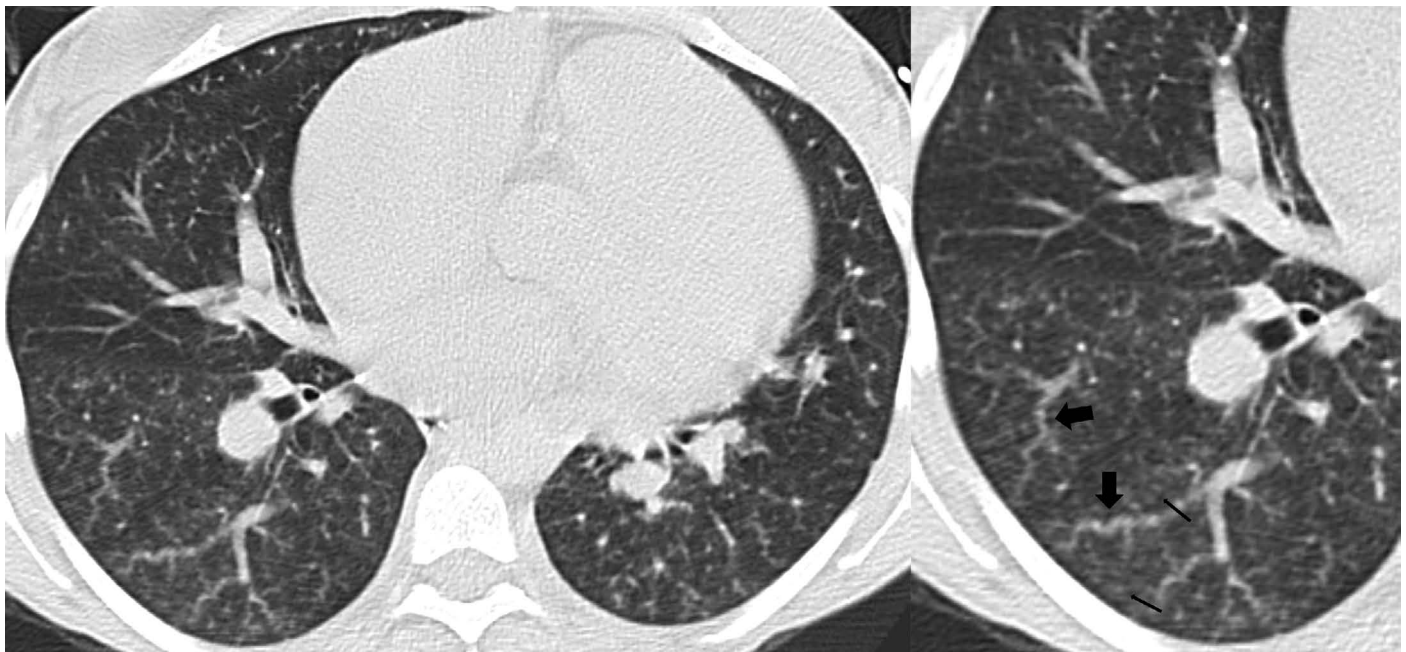
ness  $\geq 6$  mm on CT has an odds ratio (OR) of 30.5 for PH, and an RV-to-LV luminal diameter ratio of  $\geq 1.28$  carries an OR of 28.8.<sup>9</sup> Interventricular septal flattening and reflux of contrast material down the inferior vena cava also suggest RV pressure overload<sup>10</sup> (Figure 7).

### ETIOLOGIES OF PH

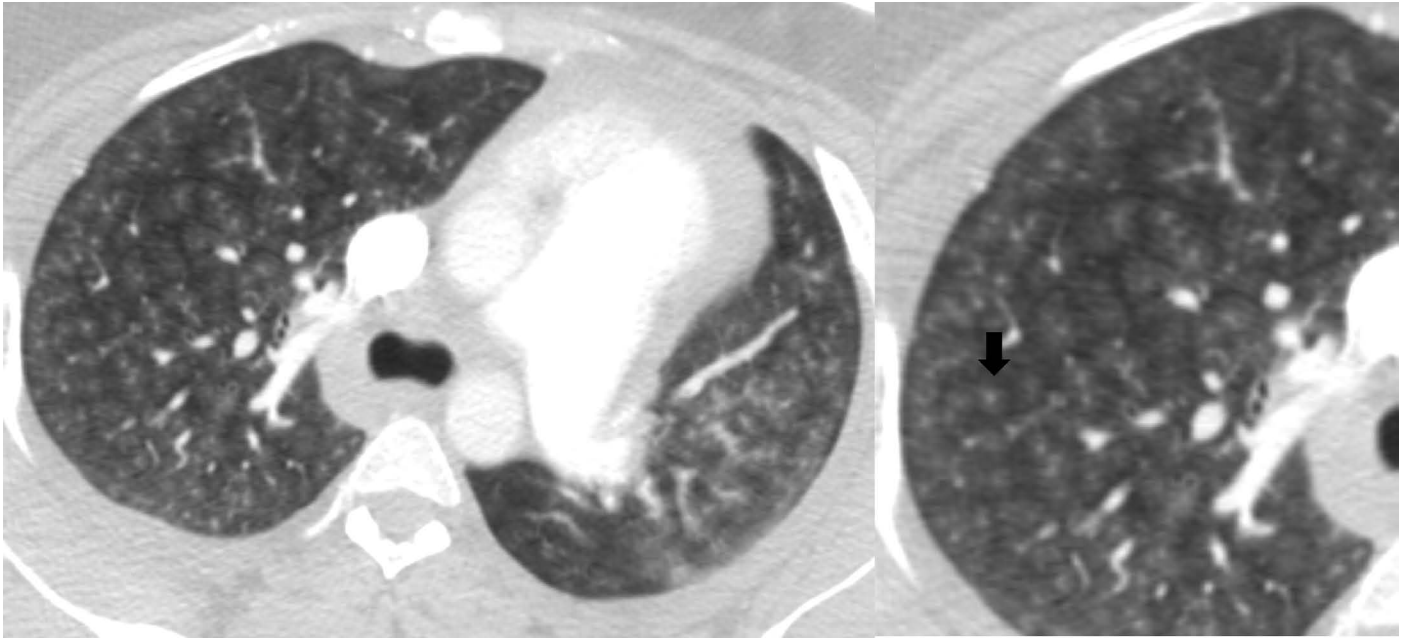
While many of the above findings may still be nonspecific to PH, if PH is strongly suspected or confirmed clinically, the following findings might provide strong clues as to the etiology of the PH. There are a few diseases that have very distinct imaging findings and usually have little extrapulmonary clinical manifestations. We have decided to group these findings in order by the proposed World Symposium on Pulmonary Hypertension clinical group classifications for PH.<sup>3,11,12</sup>

#### *Group 1*

This group is made up of a diverse set of precapillary and postcapillary diseases that lead to pulmonary arterial hypertrophy.



**Figure 8:** Computed tomographic angiogram of the chest in a 33-year-old woman with pulmonary arterial hypertension and plexogenic arteriopathy. Images show tortuous, corkscrewlike peripheral pulmonary arteries (black arrow) and faint centrilobular nodules (thin black lines).

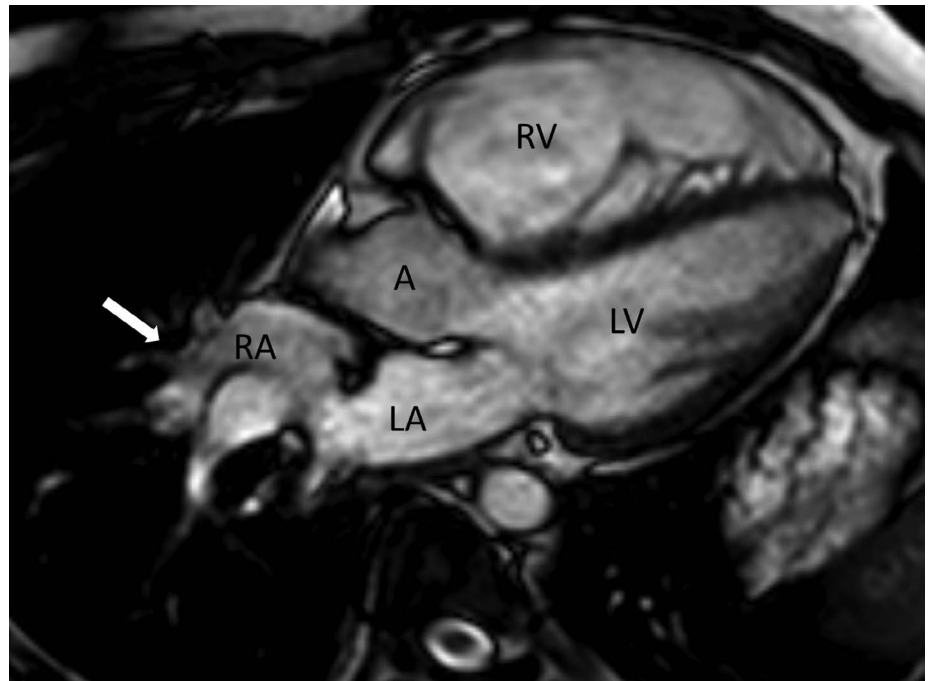


**Figure 9:** Computed tomography of the chest in a 25-year-old woman with pulmonary arterial hypertension and plexogenic arteriopathy, demonstrating ground glass attenuation centrilobular nodules with central dots representing dilated arterioles (arrow).

Plexogenic pulmonary arteriopathy is the pathognomonic histopathologic lesion of PAH,<sup>13</sup> with its presence signifying the ongoing angiogenic pathology of PAH.<sup>14</sup> The pulmonary vasculature undergoes a progression of changes from arterial medial hypertrophy to subsequent intimal proliferation and eventually compensatory plexus.<sup>15</sup> Tortuous hypertrophic arterioles may be seen peripherally as a result (Figure 8).<sup>16</sup> Poorly defined ground glass attenuation centrilobular nodules can be seen on CT (Figure 9), which might represent either the plexogenic lesions or cholesterol deposits.<sup>17</sup>

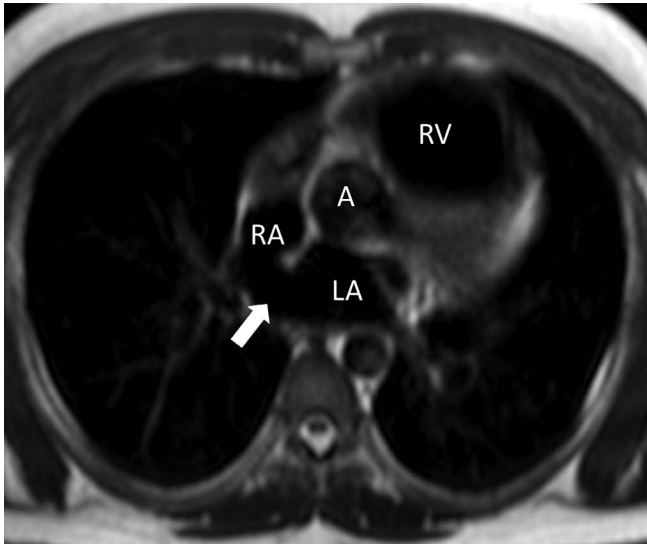
Partial anomalous pulmonary venous return (PAPVR) is an anomalous venous connection in which some pulmonary venous return drains back to the right atrium, either via direct connection or through an atrial septal defect (ASD; Figure 10), but does not cause total cyanosis as might a total anomalous connection. Left-to-right shunting is present which might eventually lead to PH. PAPVR is overall a rare finding,<sup>18</sup> but its presence should prompt search for ASD, especially a sinus venosus type of ASD if the location of PAPVR is in the right upper lobe (Figure 11), as these are highly associated.<sup>19</sup>

Pulmonary veno-occlusive disease (PVOD) is a postcapillary disease with



**Figure 10:** Steady-state free precession sequence in left ventricular outflow tract plane demonstrating the right upper lobe partial anomalous pulmonary venous return (PAPVR) draining into the superior vena cava right atrium junction (white arrow). Right atrium (RA), left atrium (LA), aorta (A), right ventricle (RV), and left ventricle (LV) are labeled on this image.

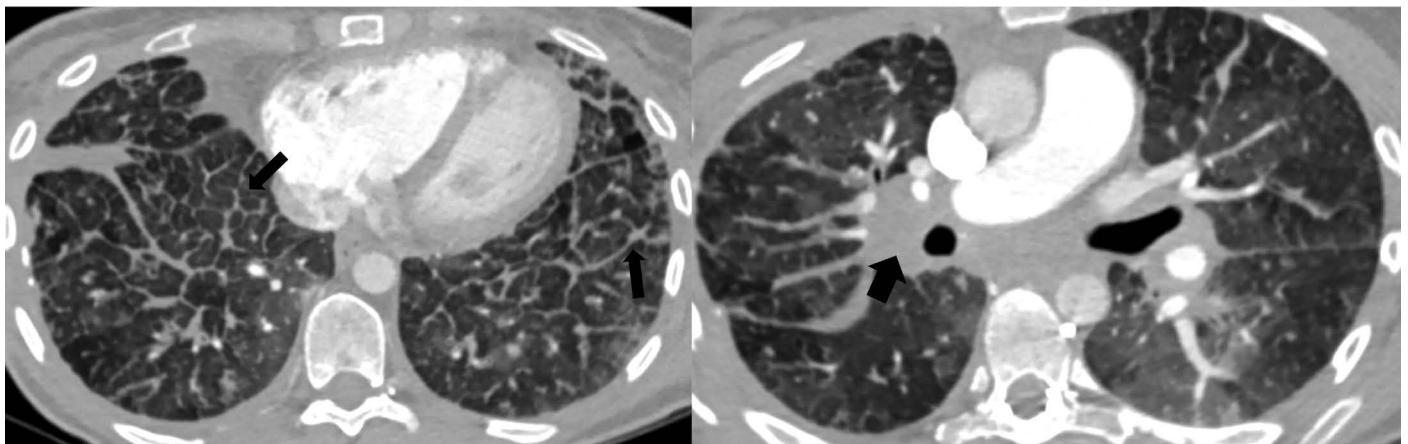




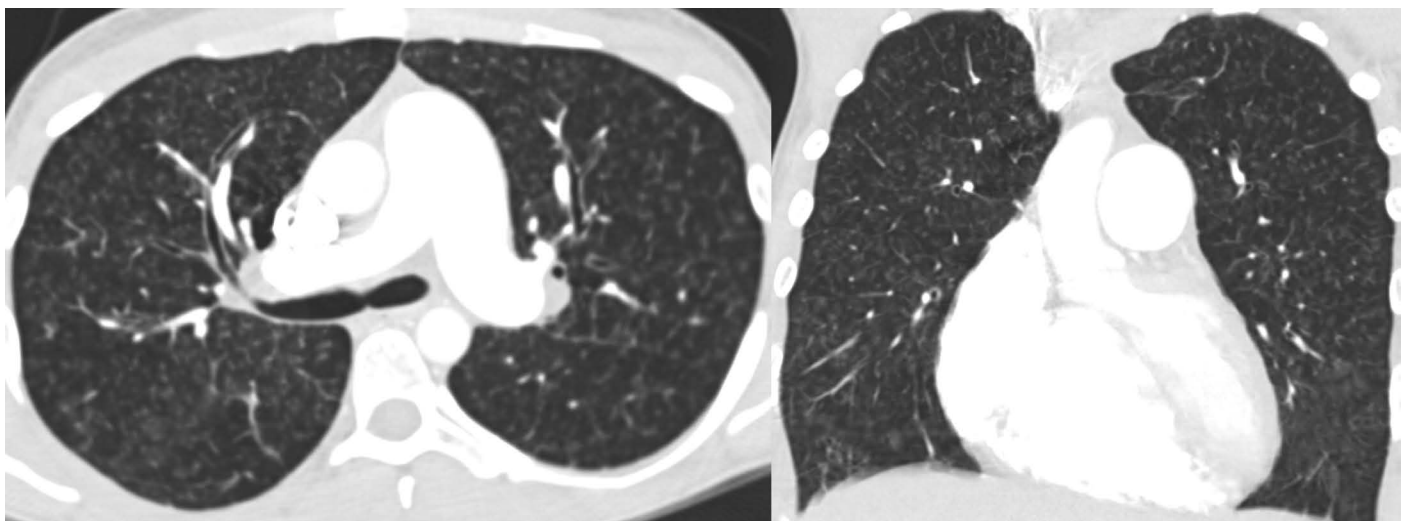
**Figure 11:** T2 black blood sequence in the same individual as in Figure 10 confirms the presence of a sinus venosus type of atrial-septal defect (white arrow). Right atrium (RA), left atrium (LA), aorta (A), right ventricle (RV), and left ventricle (LV) are labeled on this image.

characteristic findings of interlobular septal thickening, resembling the parenchymal imaging findings of left-sided heart failure without clinical evidence of left-sided congestion (Figure 12).

Pulmonary capillary hemangiomas (PCH) may be on the spectrum with PVOD as one disease.<sup>20</sup> PCH tends to present with diffuse, random ground glass attenuation nodules (Figure 13) corresponding to foci of capillary proliferation in the secondary pulmonary lobules. Characteristically, PCH is a postcapillary contributor to PH, as is PVOD. Notably, PCH and PVOD do not respond to pulmonary vasodilators, and there is an increase in risk of pulmonary edema and respiratory failure<sup>21</sup> with these advanced vasodilator therapies.



**Figure 12:** 42-year-old woman with pulmonary veno-occlusive disease (PVOD). Computed tomography of the chest demonstrating interlobular septal thickening (thin black arrow) and mediastinal and hilar lymphadenopathy (thick black arrow). These features are common to both PVOD and left-sided heart failure.



**Figure 13:** 17-year-old man with pulmonary capillary hemangiomas (PCH). Computed tomography of the chest demonstrates multiple randomly distributed ground glass attenuation nodules characteristic of PCH.

### Group 2

Chest radiography can show LV hypertrophy, as well as left atrial and ventricular dilation, all to suggest left-sided cardiomyopathy that is associated with Group 2 disease.

### Group 3

The main causes of Group 3 disease are the chronic hypoxemic respiratory diseases such as interstitial lung disease (ILD) and chronic obstructive pulmonary disease.<sup>1</sup> The role for chest CT in

making a noninvasive diagnosis for this group of diseases, particularly ILD, is well established.<sup>22</sup>

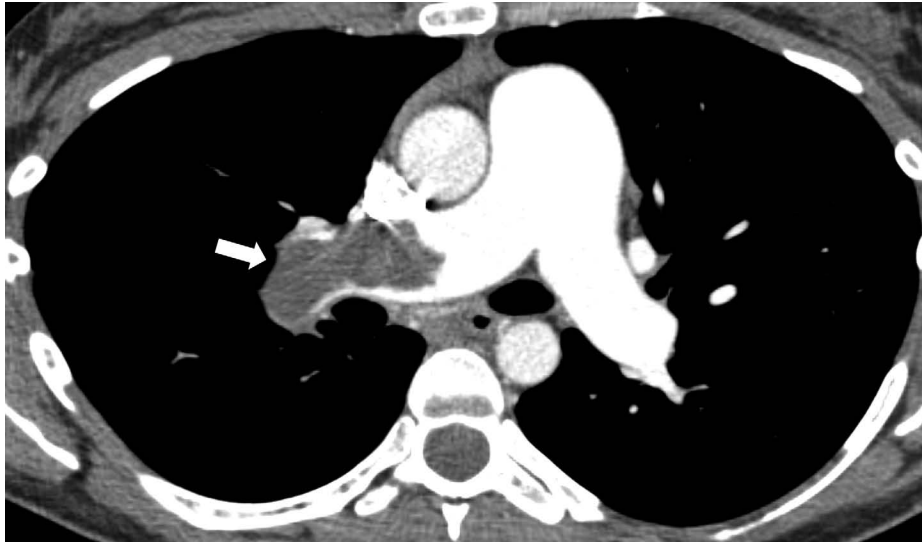
### Group 4

Chronic thromboembolic PH (CTEPH) is an underdiagnosed etiology and is often diagnosed at the same time that an individual presents with manifestations of their PH.<sup>23</sup> The diagnosis is increasingly important given advances in treatment.<sup>24–26</sup> CTEPH has several characteristic imaging features,

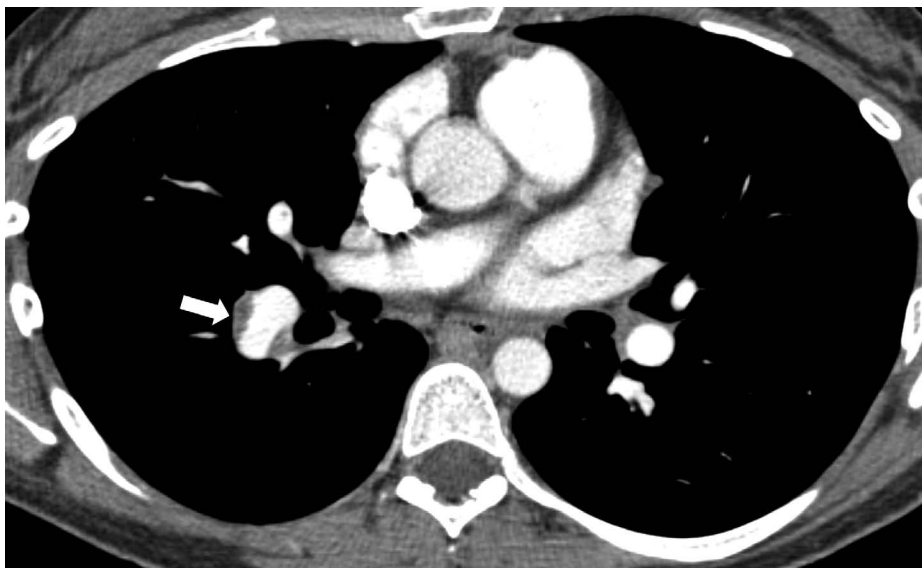
including imaging findings of acute and chronic PA thrombi (Figures 14–16), bronchial artery hypertrophy (Figures 17 and 18), and mosaic attenuation (Figures 19–21).

### Group 5

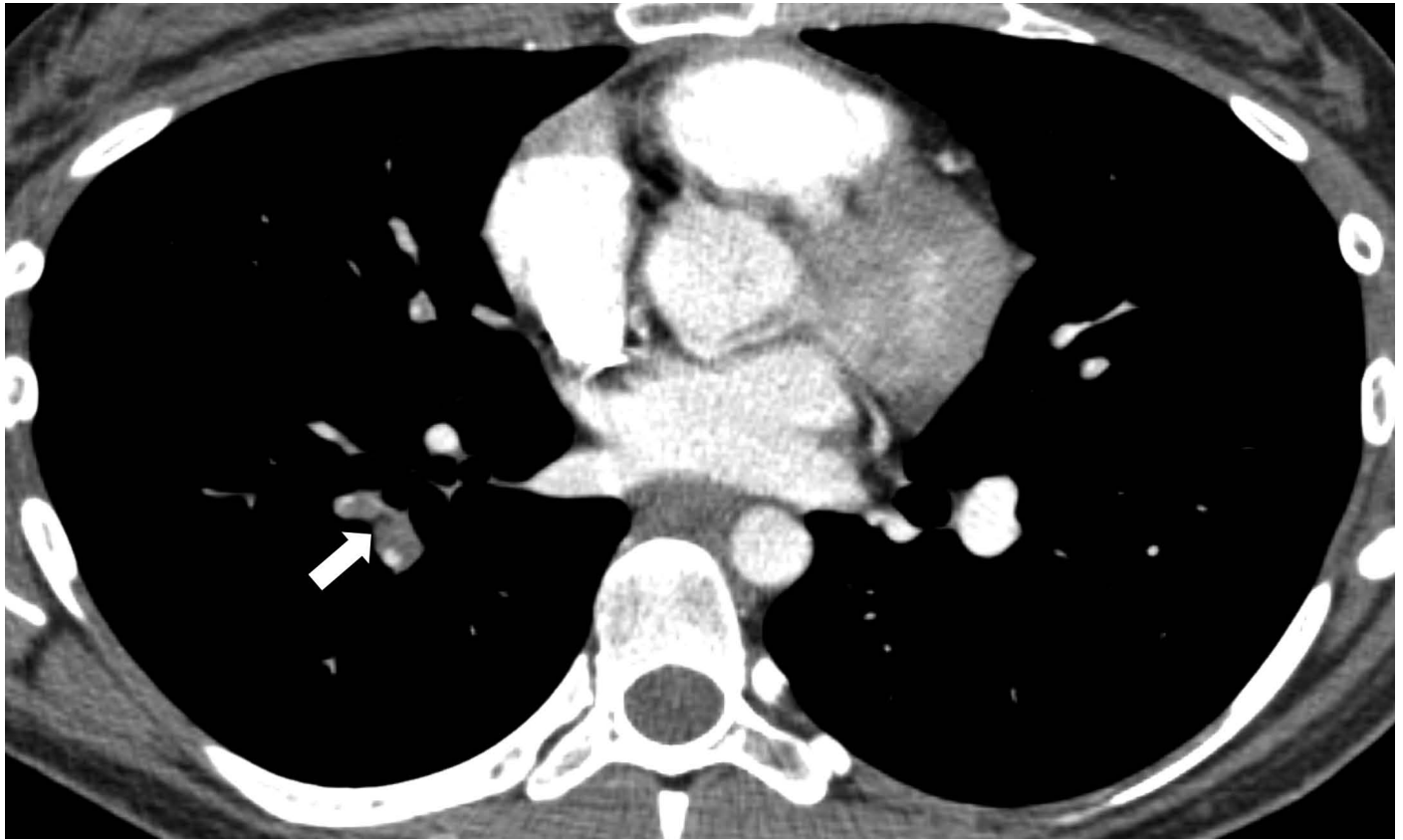
Group 5 etiologies represent a variety of diseases for which the mechanism in association with PH is not yet well understood. These include sarcoidosis and hematologic malignancies, among others.



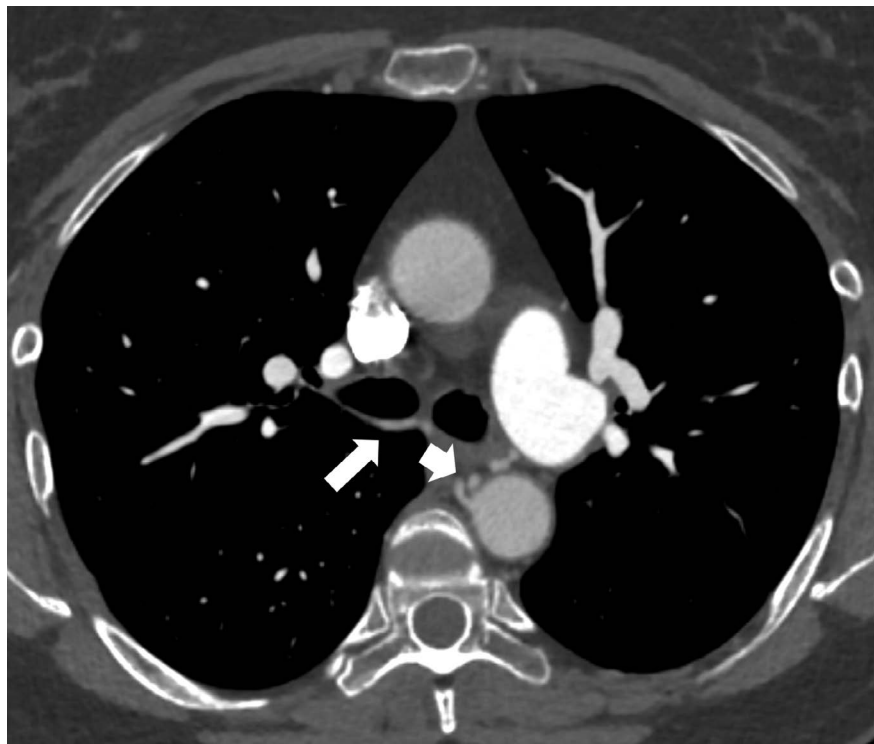
**Figure 14:** 26-year-old woman with chronic thromboembolic pulmonary hypertension. Computed tomographic angiogram of the chest shows an acute pulmonary embolism (arrow) in the right main pulmonary artery, seen as a central near-completely occlusive filling defect.



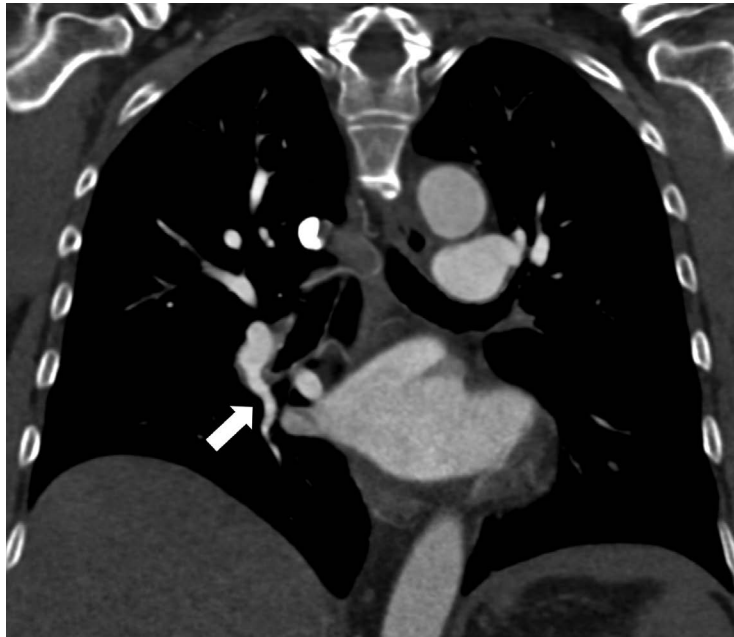
**Figure 15:** 26-year-old woman with chronic thromboembolic pulmonary hypertension (same individual as in Figure 14). Computed tomographic angiogram of the chest shows an acute pulmonary embolism in the right main pulmonary artery, seen as a central near-completely occlusive filling defect, superimposed on chronic pulmonary embolism (arrow), seen as peripheral filling defects in the basal trunk of the right lower lobe artery.



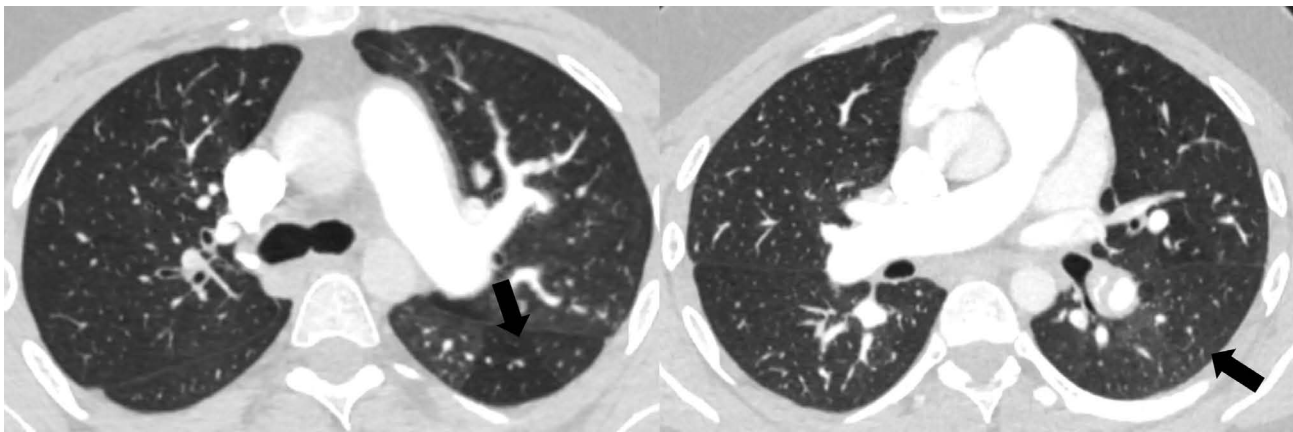
**Figure 16:** 26-year-old woman with chronic thromboembolic pulmonary hypertension (same individual as in Figures 14 and 15). Computed tomographic angiogram of the chest shows an acute pulmonary embolism in the right main pulmonary artery, seen as a central near-completely occlusive filling defect, superimposed on chronic pulmonary embolism, seen as peripheral filling defects in the basal trunk of the right lower lobe artery as well as the right lateral and posterior basal (arrow) segmental arteries.



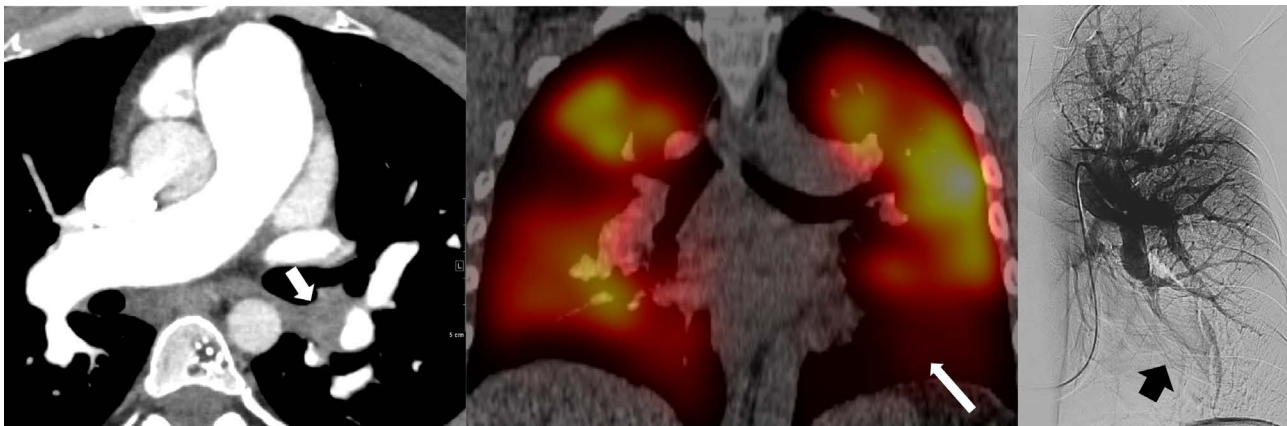
**Figure 17:** 57-year-old man with chronic thromboembolic pulmonary hypertension. Computed tomographic angiogram of the chest demonstrates bronchial artery hypertrophy (white arrows) and diminished peripheral lung vascularity.



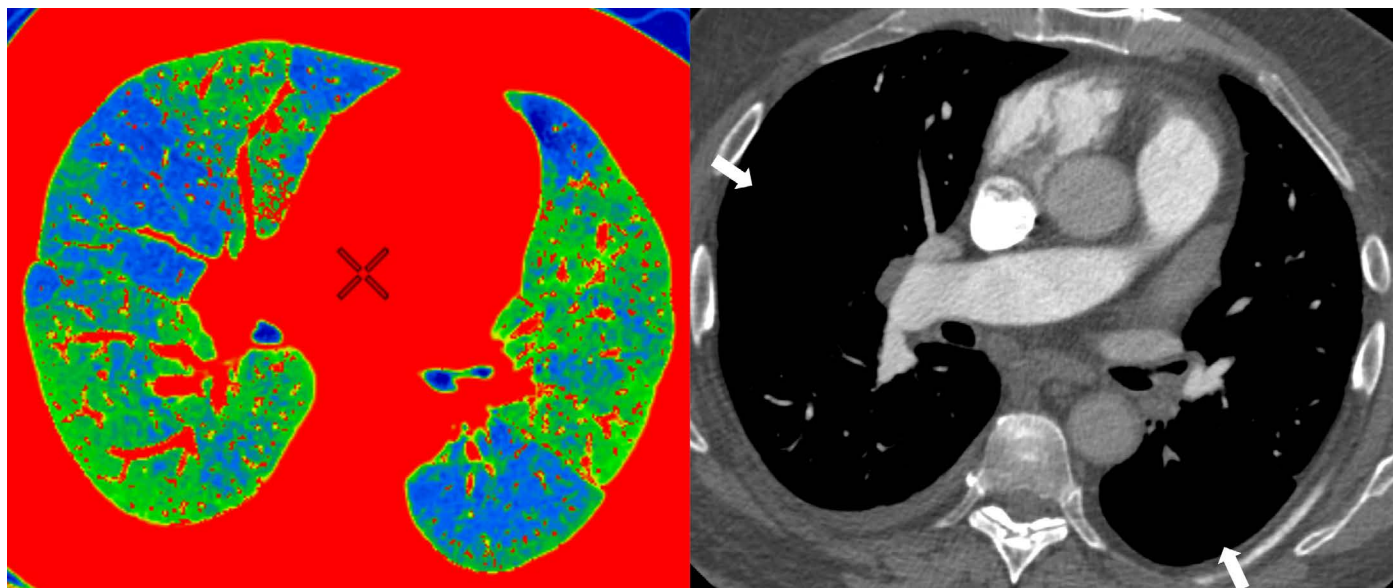
**Figure 18:** Same individual as in Figure 17. Computed tomographic angiogram of the chest in coronal projection demonstrates pulmonary artery narrowing (white arrow).



**Figure 19:** 29-year-old man with chronic thromboembolic pulmonary hypertension (CTEPH). Computed tomography of the chest demonstrating mosaic attenuation in the left lower lobe (black arrow). In individuals with pulmonary hypertension, mosaic attenuation of the lung is most commonly seen in individuals with CTEPH.<sup>9</sup>



**Figure 20:** Same individual as in Figure 19. Left panel: Computed tomographic angiogram of the chest demonstrates a chronic pulmonary embolism in the basal trunk of the left lower lobe lobar artery. Middle panel: Single photon emission computed tomography perfusion image shows decreased perfusion (white arrow) in the corresponding left lower lobe artery distribution. Right panel: Conventional pulmonary angiogram shows both occlusion of the left lower lobe pulmonary artery and corresponding loss of contrast enhancement (black arrow).



**Figure 21:** Dual-energy computed tomography (CT) with an iodine map (left panel) and corresponding CT angiogram (CTA) in mediastinal window (right panel) in a 68-year-old male with chronic thromboembolic pulmonary hypertension. Iodine map (left panel) demonstrates areas of normal perfusion seen as green, while diminished perfusion is denoted as blue. The areas of poor perfusion (blue) on the iodine map correspond to areas of diminished vascularity on the CTA image (arrow).

## CONCLUSIONS

Awareness of early and late radiographic and cross-sectional imaging features of PH may be helpful in early and accurate diagnosis. In many conditions that cause PH, imaging alone may suggest a specific etiology.

## References

1. Simonneau G, Montani D, Celermajer DS, et al. Haemodynamic definitions and updated clinical classification of pulmonary hypertension. *Eur Respir J*. 2019;53(1). doi:10.1183/13993003.01913-2018.
2. Farber HW, Loscalzo J. Pulmonary arterial hypertension. *N Engl J Med*. 2004;351(16):1655–1665. doi:10.1056/NEJMra035488.
3. McLaughlin VV, Archer SL, Badesch DB, et al. ACCF/AHA 2009 expert consensus document on pulmonary hypertension: a report of the American College of Cardiology Foundation Task Force on Expert Consensus Documents and the American Heart Association: developed in collaboration with the American College of Chest Physicians, American Thoracic Society, Inc., and the Pulmonary Hypertension Association. *Circulation*. 2009;119(16):2250–2294. doi:10.1161/CIRCULATIONAHA.109.192230.
4. Badesch DB, Raskob GE, Elliott CG, et al. Pulmonary arterial hypertension: baseline characteristics from the REVEAL registry. *Chest*. 2010;137(2):376–387. doi:10.1378/chest.09-1140.
5. Frost AE, Badesch DB, Barst RJ, et al. The changing picture of patients with pulmonary arterial hypertension in the United States: how REVEAL differs from historic and non-US contemporary registries. *Chest*. 2011;139(1):128–137. doi:10.1378/chest.10-0075.
6. Tan RT, Kuzo R, Goodman LR, Siegel R, Haasler GB, Presberg KW. Utility of CT scan evaluation for predicting pulmonary hypertension in patients with parenchymal lung disease. *Chest*. 1998;113(5):1250–1256. doi:10.1378/chest.113.5.1250.
7. Scelsi C, Bates W, Melenevsky Y, Sharma G, Thomson N, Keshavamurthy J. Egg-and-banana sign: a novel diagnostic CT marker for pulmonary hypertension. *Am J Roentgenol*. 2018;210(6):1235–1239.
8. Boerrigter B, Mauritz GJ, Marcus JT, et al. Progressive dilatation of the main pulmonary artery is a characteristic of pulmonary arterial hypertension and is not related to changes in pressure. *Chest*. 2010;138(6):1395–1401. doi:10.1378/CHEST.10-0363.
9. Barbosa EJ Jr, Gupta NK, Torigian DA, Geftter WB. Current role of imaging in the diagnosis and management of pulmonary hypertension. *AJR Am J Roentgenol*. 2012;198(6):1320–1331. doi:10.2214/AJR.11.7366.
10. Freed BH, Collins JD, François CJ, et al. MR and CT imaging for the evaluation of pulmonary hypertension. *JACC Cardiovasc Imaging*. 2016;9(6):715–732. doi:10.1016/j.jcmg.2015.12.015.
11. Correction. *Circulation*. 2009;120(2). doi:10.1161/CIRCULATIONAHA.109.192587.
12. Simonneau G, Gatzoulis MA, Adatia I, et al. Updated clinical classification of pulmonary hypertension. *J Am Coll Cardiol*. 2013;62(25):D34–D41. doi:10.1016/J.JACC.2013.10.029.
13. Prins KW, Thenappan T. World Health Organization Group I pulmonary hypertension: epidemiology and pathophysiology. *Cardiol Clin*. 2016;34(3):363–374. doi:10.1016/j.ccl.2016.04.001.
14. Cool CD, Stewart JS, Werahera P, et al. Three-dimensional reconstruction of pulmonary arteries in plexiform pulmonary hypertension using cell-specific markers: evidence for a dynamic and heterogeneous process of pulmonary endothelial cell growth. *Am J Pathol*. 1999;155(2):411–419. doi:10.1016/S0002-9440(10)65137-1.
15. Wagenvoort CA. Plexogenic arteriopathy. *Thorax*. 1994;49 Suppl:S39–S45. doi:10.1136/thx.49.suppl.s39.
16. Grosse C, Grosse A. CT findings in diseases associated with pulmonary hypertension: a current review. *Radiographics*. 2010;30(7):1753–1777. doi:10.1148/rg.307105710.
17. Nolan RL, McAdams HP, Sporn TA, Roggli VL, Tapson VF, Goodman PC. Pulmonary cholesterol granulomas in patients with pulmonary artery hypertension: chest radiographic and CT findings. *AJR Am J Roentgenol*. 1999;172(5):1317–1319. doi:10.2214/ajr.172.5.10227509.
18. Sears EH, Aliotta JM, Klinger JR. Partial anomalous pulmonary venous return presenting with adult-onset pulmonary hypertension. *Pulm Circ*. 2012;2(2):250–255. doi:10.4103/2045-8932.97637.
19. Van Praagh S, Carrera ME, Sanders SP, Mayer JE, Van Praagh R. Sinus venosus defects: unroofing of the right pulmonary veins—anatomic and echocardiographic findings and sur-

- gical treatment. *Am Heart J*. 1994;128(2):365–379. doi:10.1016/0002-8703(94)90491-X.
20. Lantuéjoul S, Sheppard MN, Corrin B, Burke MM, Nicholson AG. Pulmonary veno-occlusive disease and pulmonary capillary hemangiomas: a clinicopathologic study of 35 cases. *Am J Surg Pathol*. 2006;30(7):850–857. doi:10.1097/01.pas.0000209834.69972.e5.
  21. Montani D, Achouh L, Dorfmüller P, et al. Pulmonary veno-occlusive disease: clinical, functional, radiologic, and hemodynamic characteristics and outcome of 24 cases confirmed by histology. *Medicine (Baltimore)*. 2008;87(4):220–233. doi:10.1097/MD.0b013e31818193bb.
  22. Travis WD, Costabel U, Hansell DM, et al. An official American Thoracic Society/European Respiratory Society statement: update of the international multidisciplinary classification of the idiopathic interstitial pneumonias. *Am J Respir Crit Care Med*. 2013;188(6):733–748. doi:10.1164/rccm.201308-1483ST.
  23. Fedullo PF, Auger WR, Kerr KM, Rubin LJ. Chronic thromboembolic pulmonary hypertension. *N Engl J Med*. 2001;345(20):1465–1472. doi:10.1056/NEJMra010902.
  24. Mizoguchi H, Ogawa A, Munemasa M, Mikouchi H, Ito H, Matsubara H. Refined balloon pulmonary angioplasty for inoperable patients with chronic thromboembolic pulmonary hypertension. *Circ Cardiovasc Interv*. 2012;5(6):748–755. doi:10.1161/CIRCINTERVENTIONS.112.971077.
  25. Kataoka M, Inami T, Hayashida K, et al. Percutaneous transluminal pulmonary angioplasty for the treatment of chronic thromboembolic pulmonary hypertension. *Circ Cardiovasc Interv*. 2012;5(6):756–762. doi:10.1161/CIRCINTERVENTIONS.112.971390.
  26. Rivers-Bowerman MD, Zener R, Jaber A, et al. Balloon pulmonary angioplasty in chronic thromboembolic pulmonary hypertension: new horizons in the interventional management of pulmonary embolism. *Tech Vasc Interv Radiol*. 2017;20(3):206–215. doi:10.1053/j.tvir.2017.07.011.

# When a Clot Is Not a Clot: An Unusual Cause of Progressively Worsening Dyspnea in a Previously Healthy Woman

*Section Editor*

Deborah J. Levine, MD

Nicholas Fox, MD  
*Pulmonary, Critical Care and Sleep  
Medicine*  
Medical University of South Carolina  
Charleston, SC

Victor Test, MD  
*Pulmonary Critical Care Medicine*  
Duke University Medical Center  
Durham, NC

Vinod Jona, MD  
*Pulmonary and Critical Care*  
McLeod Health System  
Florence, SC

Russell Harley, MD  
*Pulmonary, Critical Care and Sleep  
Medicine*  
Medical University of South Carolina  
Charleston, SC

Rahul G. Argula, MD  
*Pulmonary, Critical Care and Sleep  
Medicine*  
Medical University of South Carolina  
Charleston, SC

## PRESENTATION

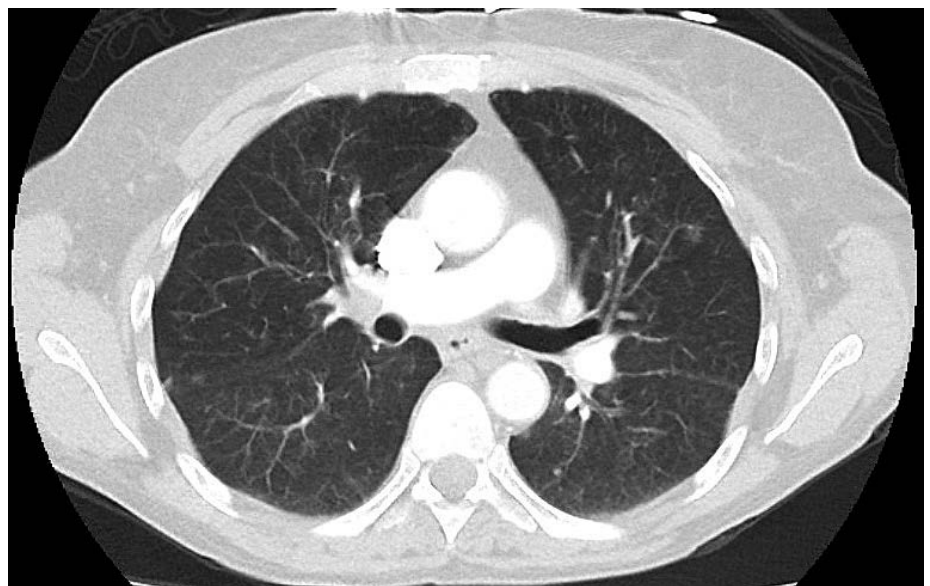
A 61-year-old Caucasian female presented with a 4-month history of dyspnea on exertion. She was previously healthy, worked out regularly, and had no prior tobacco exposure. Her symptoms were preceded by a sharp, inspiratory chest pain (left sided), which was initially intermittent and later became persistent. A few days into her symptom course, she developed exertional dyspnea. A contrasted high-resolution computed tomography (HRCT) scan of the chest ordered by her primary care provider showed minimal, peripheral-appearing upper lobe and right middle lobe ground-glass opacities without any evidence of pulmonary emboli (PE) (Figure 1). She was given a course of antibiotics, 20 mg of prednisone for 5 days, and referred to a pulmonologist. With this, her chest pain improved but her dyspnea persisted. At the pulmonary evaluation a few weeks later, she was noted to be significantly hypoxemic. She was started on supplemental oxygen therapy. Given her persistent symptoms, she received 3 different additional courses of oral antibiotic therapy for a possible “resistant” pneumonia to no avail. Given the lack of improvement in her symptoms, her prednisone dose

was increased, and she was subsequently referred to our institution.

## ASSESSMENT

On physical examination at the time of initial evaluation at our institution, the patient was afebrile with pulse oximetry revealing an oxygen saturation of 100% on 5 L/min of supplemental oxygen. Oral exam was notable for several tel-

angiectasias on her hard palate. Cardiac and pulmonary exams were unremarkable with a normal sounding P2 and no murmurs. Jugular venous pulse was not elevated. Musculoskeletal exam was negative for muscle or joint tenderness. On skin exam, several telangiectasias were noted across her anterior chest wall. There was no evidence of sclerodactyly or digital ulceration. There was neither



**Figure 1:** Initial contrasted chest computed tomography with minimal, peripheral, ground-glass opacities. No evidence of acute pulmonary emboli.

**Table 1.** Pertinent PFT Values (PFTs Notable for Reduction in  $D_LCO$ )

PFT parameters	Predicted	Measured	% Predicted
FVC, L	2.88	3.23	112%
FEV1	2.22	2.50	113%
FEV/FVC, %		77	
TLC, L	4.20	4.89	116%
RV, L	1.58	1.66	105%
$D_LCO$ , mL/mm Hg per minute	16.6	9.3	56%

Abbreviations: PFT indicates pulmonary function test;  $D_LCO$ , diffusing capacity of the lungs for carbon monoxide; FVC, forced vital capacity; FEV1, forced expiratory volume in 1 second; TLC, total lung capacity measured using plethysmography; RV, residual volume.

cyanosis nor edema at the peripheries of her extremities. Her neurologic exam was also unremarkable.

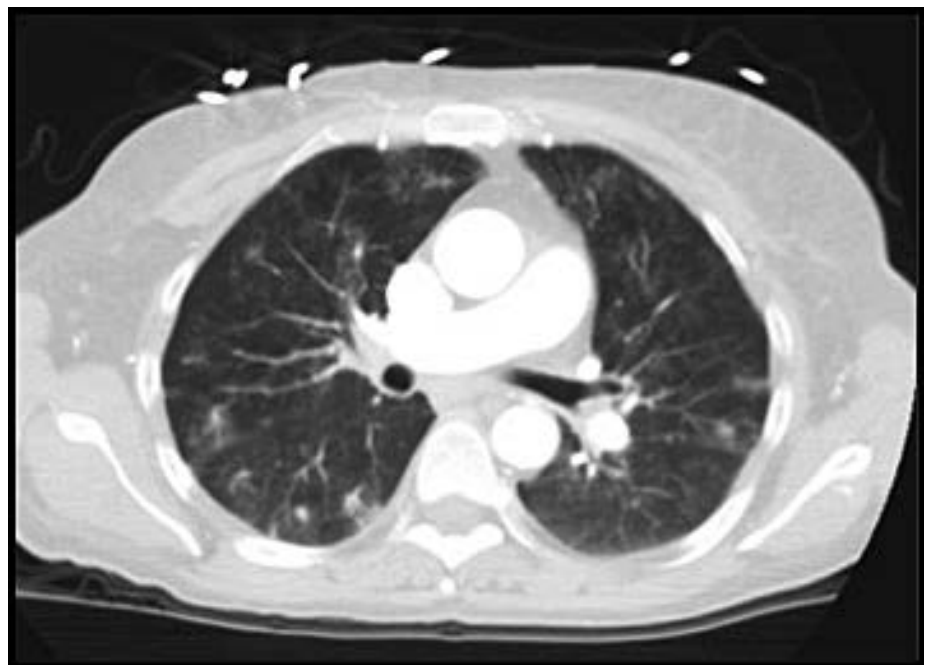Her pulmonary function tests were normal except for an isolated reduction in the diffusing capacity of the lungs for carbon monoxide ( $D_LCO$ ) (Table 1). Her 6-minute walk distance was reduced at 290 m with a significant oxygen desaturation to 92% on 4 L/min. Her initial laboratory workup demonstrated a normal complete blood cell count panel as well as normal renal and liver function panels, and her serum levels of cardiac biomarkers were within normal limits. Her electrocardiogram was unremarkable as was her chest x-ray. We then ordered a repeat contrasted HRCT scan of her chest which demonstrated a worsening of the previously described airspace opacities. Her imaging now showed increased prominence of the upper lobe ground-glass opacities, again without any evidence of acute PE. The airspace opacities were peripheral in position and appeared to have a vascular predilection, and some of the opacities had a nodular appearance to them (Figure 2). An echocardiogram demonstrated a preserved ejection fraction with normal left and right ventricular size and function. There were no signs of valvulopathy or pulmonary hypertension (PH).

## MANAGEMENT AND MONITORING

Further workup was pursued with an extensive autoimmune panel, including a myositis antibody panel and a hypersensitivity antibody panel, all of which were negative. Her creatine kinase level was within normal limits. Eventually, she un-

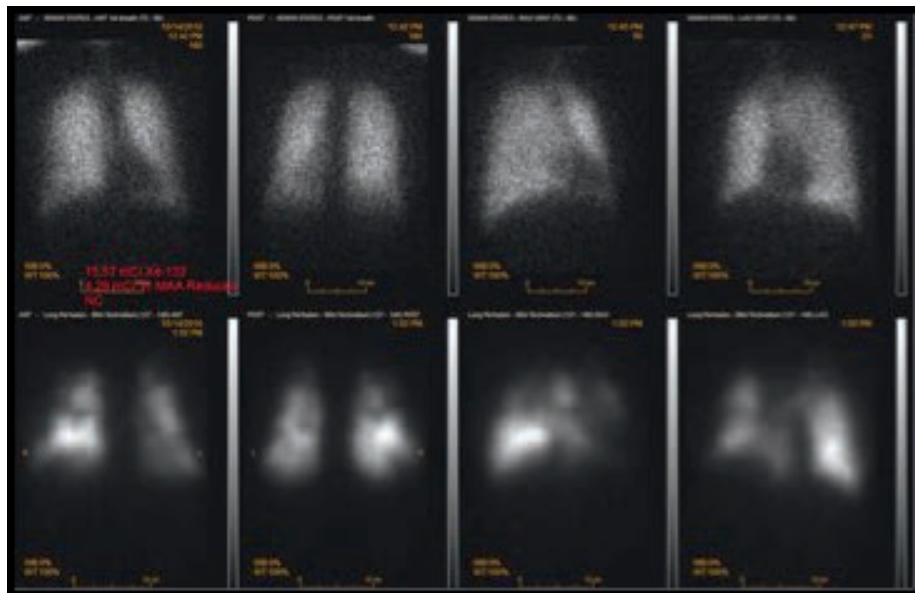
derwent a bronchoscopy with transbronchial biopsies, which were unrevealing. Broncho-alveolar lavage was noted to be lymphocyte predominant. Cytology was unremarkable and negative for fungal organisms and malignant cells. Cryptogenic organizing pneumonia was the initial diagnosis of exclusion and so she was started on therapy with high-dose prednisone (1 mg/kg) and concomitant pneumocystis prophylaxis with trimethoprim-sulfamethoxazole. With steroid therapy, her symptoms improved initially, and her oxygen requirement decreased to 3 L/min during rest. However, after 8 weeks on high-dose prednisone, she returned to the clinic with worsening dyspnea and hypoxemia.

Given her persistent symptoms, low  $D_LCO$ , a vascular distribution of her airspace opacities, and severe hypoxemia, pulmonary vascular disease continued to remain a possibility. She then underwent a ventilation/perfusion (V/Q) scan that returned positive for bilateral unmatched wedge-shaped perfusion defects, suggestive of pulmonary thromboembolic disease (Figure 3). Pulmonary veno-occlusive disease (PVOD) was also entertained as a possibility given her profound hypoxemia. She was started on systemic anticoagulation with rivaroxaban. A subsequent evaluation with a hypercoagulable panel did not reveal any underlying thrombophilia. A right heart catheterization (RHC) was consistent with mild PH and an elevated pulmonary vascular resistance (Table 2). She was then referred to the nearest pulmonary thrombo-endarterectomy center where a fluoroscopic pulmonary angiogram was completed. Interestingly, her pulmonary angiogram did not show any filling defects in the pulmonary vascular tree. The venous phase of the angiogram also showed normal emptying, making this unlikely to be pulmonary thromboembolic disease or PVOD. Ultimately, without a clear diagnosis, we pursued an urgent video-assisted



**Figure 2:** Repeat contrasted chest computed tomography with increased number and prominence of the peripheral, ground-glass opacities. No evidence of acute pulmonary emboli.





**Figure 3:** Planar ventilation/perfusion (V/Q) scan images demonstrating bilateral unmatched, wedge-shaped perfusion defects.

thoroscopic surgery lung biopsy, which provided a definitive diagnosis.

## DISCUSSION AND CLINICAL REASONING

Though there was no evidence by history or on exam of a systemic autoimmune process, we checked both autoimmune and myositis antibody panels. These panels returned negative as did a hypersensitivity pneumonitis antibody panel. Considering her unremarkable aero-allergen exposure history and that her pulmonary function tests demonstrated normal estimates of lung volume by spirometry and plethysmography, we felt reassured that an interstitial lung disease was unlikely. However, the isolated  $D_LCO$  on her pulmonary function tests continued to keep occult pulmonary vascular disease on the list of differential diagnoses. With her degree of hypoxemia and noting the peripheral and vascular distribution of the pulmonary opacities, we pursued a V/Q scan to evaluate for any possible microvascular pulmonary thromboembolic disease. The identification of at least two mismatched segmental perfusion defects (perfusion defects noted in areas of the lung with normal ventilation) on planar imaging is considered “high probability” for PE by the Prospective Investigation of Pulmonary Embolism Diagnosis study’s criteria.<sup>1</sup> In patients with suspected

chronic thromboembolic PH (CTEPH), a V/Q scan is more “sensitive” as it can detect distal and subsegmental perfusion defects that can often be missed on contrast-enhanced chest CT imaging.<sup>2</sup>

Progressive dyspnea on exertion, a decreased 6-minute walk distance, and an isolated low  $D_LCO$  in concert with a chest CT negative for acute PE should prompt consideration of pulmonary vascular disease. Chronic thromboembolic disease (CTED) and CTEPH are two causes of pulmonary vascular disease due to thromboembolic events. CTEPH can occur in 0.4% to 8.8% of patients who develop an acute PE.<sup>3</sup> One-half of patients with CTEPH do not recall ever having had a diagnosis of PE.<sup>4</sup> A diagnosis of CTEPH becomes obvious typically following 6 months after the index PE event. CTED is diagnosed in patients who have imaging evidence of embolic burden in the pulmonary vasculature but do not have RHC-documented PH.<sup>5</sup> Both CTEPH and CTED are diagnosed by means of a V/Q scan and can reportedly be associated with normal-appearing pulmonary arteries on contrasted chest CT imaging in a significant number of patients. Our patient’s V/Q scan was positive for multiple perfusion defects (Figure 3) but contrasted CT imaging did not reveal any filling defects in the pulmonary arteries. An RHC is also important for

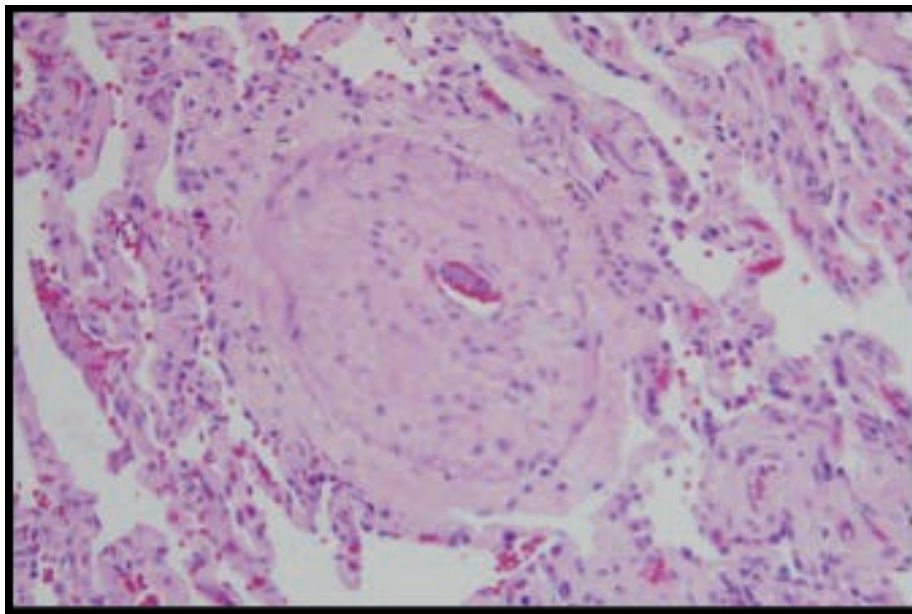
**Table 2.** Right Heart Catheterization

RHC variable	Value
RAP	4 mm Hg
RVP	41/2 mm Hg
PAP	42/18 mm Hg
mPAP	27 mm Hg
PCWP	6 mm Hg
CO (Fick)	4.2 L/min
CI	2.8 L/min per m <sup>2</sup>
PVR	5.0 Wood units
SaO <sub>2</sub> sat	94.7%
PAO <sub>2</sub> sat	70.4%

Abbreviations: RHC indicates right heart catheterization; RAP, right atrial pressure; RVP, right ventricular pressure; PAP, pulmonary arterial pressure; mPAP, mean pulmonary arterial pressure; PCWP, pulmonary capillary edge pressure; CO, cardiac output as measured by Fick equation; CI, cardiac index; PVR, pulmonary vascular resistance; SaO<sub>2</sub> sat, systemic oxygen saturation; PAO<sub>2</sub> sat, pulmonary artery oxygen saturation.

the diagnosis of CTEPH. Despite this patient’s echocardiogram being normal, an RHC was pursued (Table 2). This was followed by a dedicated fluoroscopic pulmonary angiogram to determine the pulmonary vascular thrombotic burden contributing to her PH. The findings of mildly elevated pulmonary pressures, moderately elevated pulmonary vascular resistance, and the absence of a significant clot burden on pulmonary angiography were inconsistent with a diagnosis of significant CTEPH. Her pulmonary hemodynamics and unremarkable venous-phase emptying noted on the pulmonary angiogram were also inconsistent with PVOD, another diagnosis which was considered.<sup>6</sup>

While the diagnosis remained elusive, the patient continued to have a functional decline with increasing oxygen requirement. As her clinical picture remained concerning for a pulmonary vascular disease, we revised our list of differential diagnoses to include atypical vasculitis, an embolic or malignant phenomenon, and although less likely, we left PVOD on the differential. Considering that there was no evidence of an infectious source by exam or blood work, septic PE was also considered an



**Figure 4:** Pulmonary artery, with intimal proliferation and intraluminal lymphoma cells. The lumen is severely narrowed due to the lymphomatous cell burden in the vessel.

unlikely diagnosis. As previously mentioned, there was no serologic evidence supporting the diagnosis of a rheumatologic disorder or pulmonary vasculitis. Other conditions that may result in pulmonary perfusion abnormalities and had previously been described in the extant literature included fat emboli, pulmonary capillary hemangiomatosis, pulmonary vasculitis, and pulmonary tumor emboli.<sup>7</sup>

Ultimately, the patient underwent a surgical lung biopsy via video-assisted thoracoscopic surgery to get a definitive diagnosis. The pathology was consistent with a primary pulmonary intravascular large B-cell lymphoma (IVLBCL) (Figure 4).

Pulmonary IVLBCL is an extremely rare type of extranodal large B-cell lymphoma first described by Pflieger and Tappeiner in 1958.<sup>8</sup> This disease is characterized by a distinct proliferation of lymphomatous cells within the pulmonary microvasculature. Clinical symptoms and signs result from a compromised blood flow in the pulmonary capillaries. Pulmonary capillaries are particularly vulnerable while larger arteries and veins are typically spared, resulting in a significant gas exchange derangement. While lung involvement is common, it is rare for the primary presentation to be isolated to the lungs.

Common presenting features include fever, weight loss, and anemia; however, the presentation varies depending on the organ(s) affected.<sup>9</sup> With regard to primary pulmonary disease, dyspnea, cough, and hypoxemia are the most notable symptoms. The CT findings are variable but include ground-glass opacities, centrilobular nodules, and interlobular septal thickening. Tissue biopsy by transbronchial biopsy or surgical lung biopsy remains the “gold standard” for diagnosis. The prognosis for this aggressive lymphoma is typically poor, often due in part to a delay in diagnosis.<sup>10</sup> Unfortunately, in a significant number of cases the diagnosis is often arrived at by autopsy.

For our patient, the persistent and systematic pursuit of a diagnosis despite conflicting data (positive V/Q scan in absence of discernable risk factors for venous thromboembolism) helped us arrive at this diagnosis in a timely fashion. She received 6 cycles of a chemotherapy regimen of rituximab, cyclophosphamide, doxorubicin, vincristine, and prednisone under the supervision of a malignant-hematology specialist. She responded very well and was weaned off supplemental oxygen quickly following a remission of her disease. Currently, she is over 18 months from her last chemotherapy dose. She reported no physical

limitations at her last evaluation. Her lymphoma remains in remission.

## CONCLUSION

Primary pulmonary IVLBCL.

### Teaching Points

1. A V/Q scan is sensitive for detecting perfusion defects in both PE and CTEPH.
2. A contrast-enhanced CT scan of the chest can be falsely negative in up to 49% of patients with CTEPH.
3. The differential diagnosis for perfusion defects on V/Q scan includes CTEPH, pulmonary vasculitis, pulmonary capillary hemangiomatosis, tumor emboli, and fat emboli.
4. Primary pulmonary IVLBCL is a rare type of B-cell lymphoma. It is characterized by proliferation of lymphomatous cells within the pulmonary microvasculature.
5. Primary pulmonary IVLBCL is a rare condition that can mimic CTEPH due to the tumoral cell occlusion of the pulmonary microvasculature. Lung biopsy is the only definitive way of diagnosis. Early diagnosis can result in a potential remission.

### References

1. Sostman HD, Miniati M, Gottschalk A, Matta F, Stein PD, Pistolesi M. Sensitivity and specificity of perfusion scintigraphy combined with chest radiography for acute pulmonary embolism in PIOPED II. *J Nucl Med*. 2008;49(11):1741-1748.
2. Tunariu N, Gibbs SJ, Win Z, et al. Ventilation-perfusion scintigraphy is more sensitive than multidetector CTPA in detecting chronic thromboembolic pulmonary disease as a treatable cause of pulmonary hypertension. *J Nucl Med*. 2007;48(5):680-684.
3. Yang S, Yang Y, Zhai Z, et al. Incidence and risk factors of chronic thromboembolic pulmonary hypertension in patients after acute pulmonary embolism. *J Thorac Dis*. 2015;7(11):1927-1938.
4. McLaughlin VV, Archer SL, Badesch DB, et al. ACCF/AHA 2009 expert consensus document on pulmonary hypertension a report of the American College of Cardiology Foundation Task Force on Expert Consensus Documents and the American Heart Association developed in collaboration with

- the American College of Chest Physicians; American Thoracic Society, Inc.; and the Pulmonary Hypertension Association. *J Am Coll Cardiol.* 2009;53(17):1573-1619. doi: 10.1016/j.jacc.2009.01.004.
5. Kim NH, Delcroix M, Jais X, et al. Chronic thromboembolic pulmonary hypertension. *Eur Respir J.* 2019;53(1):10.1183/13993003.01915-2018. Print 2019 Jan. doi: 1801915.
  6. Scheibel RL, Dedeker KL, Gleason DF, Pliego M, Kieffer SA. Radiographic and angiographic characteristics of pulmonary veno-occlusive disease. *Radiology.* 1972;103(1):47-51. doi: 10.1148/103.1.47.
  7. Broaddus VC, Mason RJ, Ernst JD, et al. *Murray and Nadel's Textbook of Respiratory Medicine.* 6th ed. Amsterdam: Elsevier; 2016.
  8. Pflieger L, Tappeiner J. On the recognition of systematized endotheliomatosis of the cutaneous blood vessels (reticuloendotheliosis?) *Hautarzt.* 1959(10):359-363.
  9. García-Muñoz R, Rubio-Mediavilla S, Robles-de-Castro D, Muñoz A, Herrera-Pérez P, Rabasa P. Intravascular large B cell lymphoma. *Leuk. Res Rep.* 2014;3(1):21-23.
  10. Chen Y, Ding C, Lin Q, Yang K, Li Y, Chen S. Primary intravascular large B-cell lymphoma of the lung: a review and case report. *J Thorac Dis.* 2014;6(10):E242-E245.

# Facilitating and Improving Adherence: The Development of a Pulmonary Arterial Hypertension Self-Care Management Agreement

*Section Editor*

Traci Housten, RN, MS

Jacqueline M. Brewer, AGPCNP-BC  
*Pulmonary Specialty Center  
 Beaumont Health  
 Troy, MI*

Samuel A. Allen, DO, FCCP  
*Pulmonary Specialty Center  
 Beaumont Health  
 Troy, MI*

Successful disease management includes improvement in a patient's quality of life, particularly when working with patients suffering from pulmonary arterial hypertension (PAH). This success is achieved through a team approach between patients, families, and their health care providers. Providers often prescribe treatment regimens and offer recommendations to slow disease progression and allow patients to become more functional. Adherence to these regimens is critical to the patients' overall morbidity and mortality. Failure to adhere to the recommendations set forth by health care providers often leads to clinical worsening and increased health care costs.<sup>1</sup> We will briefly examine the issue of medication nonadherence and how the development of a self-care responsibilities agreement changed the practice of one pulmonary hypertension (PH) center for the better.

The World Health Organization (WHO) defines medication adherence as "the degree to which the person's behavior corresponds with the agreed recommendations from a health care provider."<sup>1</sup> Perhaps one of the greatest challenges health care providers face is the matter of patient nonadherence. The prevalence of medication nonadherence is astonishing: "In some disease conditions, more than 40% of patients sustain significant risks by misunderstanding, forgetting, or ignoring health care advice."<sup>2</sup> Medication nonadherence

can range from never filling a prescription, to stopping medication without notifying the prescriber, to not taking a medication as prescribed, or by not following the recommendations associated with a prescribed medication.<sup>1</sup> The overall outcome of such behavior has adverse consequences. These consequences include "waste of medication, disease progression, reduced functional abilities, a lower quality of life, and increased use of medical resources such as nursing homes, hospital visits, and hospital admissions."<sup>2</sup>

In the field of PAH, the consequences of medication nonadherence can be dangerous and often life threatening, particularly when working with parenteral prostacyclins. PAH medications are unique and complex and warrant a level of respect regarding their safety profiles. In our PH practice, various methods were employed in an effort to prevent nonadherence and improve patient outcomes. These methods included forming a personal connection and level of trust between patient and provider. Additionally, a substantial amount of time was spent educating on disease management and medication nuances. Despite these methods, nonadherence was present in our practice.

In an effort to address the issue of nonadherence, parenteral prostacyclin patients in our practice were observed over a 6-month period. These patients in particular were chosen because of the

risks associated with nonadherence in this specific medication category. Patient interactions occurred during inpatient and outpatient encounters to substantiate evidence of adherence with particular safety measures discussed at length with patients during various training/education sessions. The results of this survey demonstrated gaps in what parenteral prostacyclin patients were taught, comprehended, and what was actually being practiced concerning medication safety. These results indicated that further measures were required to ensure medication adherence, safety, and overall patient wellness.

Our program initiated a thoughtful review of the literature to deepen our understanding of patient adherence and strategies that had the potential to change baseline behavior. Medical entities incorporating the use of contracts or agreements to increase medication adherence were investigated, particularly in the field of pain management. The research showed that the effectiveness of such documents regarding opioid use remained unclear. However, there is absolutely *no* research involving the use of such a document in the realm of medication adherence and PAH. Moreover, based on research involving opioid therapy, the use of the term "contract" was highly detested, as it "can be perceived as coercive, can erode physician-patient trust, and implies that failure to agree will result in loss of access."<sup>3</sup> It became clear that verbiage used in these kinds of documents could stigmatize patients. The language chosen could be implied as "mistrustful, accusatory, and even

Correspondence: thoust1@jhmi.edu

Disclosure: The authors have no relevant personal financial relationships to disclose.

confrontational.”<sup>3</sup> Therefore, special care needed to be taken when writing such a document. The term “contract” would not be used for the development of an agreement for our PAH purposes.

Based on these research efforts, a PAH self-care responsibilities agreement was developed in order to increase adherence and hold patients and PH team members accountable for discussing and agreeing upon various measures to increase safety and overall health. It was decided among all members of the PH team that this self-care responsibilities agreement would be extended to include all PAH patients on drug therapy, not just parenteral prostacyclin patients as initially planned. It should be noted that a discussion occurred with the hospital legal department, who indicated this would not be a legally binding document.

Over the next 4 weeks, a self-care responsibilities agreement was drafted in collaboration with the PH team including physicians, nurses, and nurse practitioners. This agreement was narrowed to 14 key points deemed necessary for discussion once starting the treatment for PAH. These points ranged from understanding the diagnosis of PAH and the medications prescribed, to the risks of pregnancy and the use of contraception, to not stopping PAH therapies for any reason without discussing with the PH team. A sample of the agreement is included in the Appendix. Each patient was provided a copy of the agreement to read privately. Subsequently, time was

allotted to provide further education, discuss benefits, and engage each patient in discussion regarding the points within the agreement. The patient was made aware that the agreement was not a legally binding document. They were then asked to sign the agreement along with a PH team member. This agreement was then scanned into the patient's electronic medical record. By placing this agreement into the patient's chart, it allowed the PH team access to the signed agreement in order to reexamine when necessary if the plan was not being followed or as a refresher for both the PH team and patient in the future.

Patients on all forms of medication therapy for the treatment of PAH were reassessed during inpatient visits and follow-up outpatient appointments for adherence, understanding, and recollection of the key points within the self-care responsibilities agreement. We did not formally score or track adherence issues before and after implementation of the self-care agreement. However, we believe that over the course of 1 year, the gap that had previously existed involving adherence with PAH medications and safety measures prior to the self-care responsibilities agreement had narrowed. Patients appeared more adherent to the safety measures and treatment plan set in place, especially those on parenteral prostacyclins. The level of education, discussion, and shared decision making between the patient and PH team, based on the self-care responsibilities agreement, generated an environment

of respect that could ultimately lead to better patient outcomes.

Nonadherence to medication regimens and recommended treatment best practices is a serious challenge that patients and providers struggle with daily. Nonadherence leads to increased health care costs and an overall risk to a patient's health and wellness. Patients with PAH are often prescribed medications and plans of care that, if not followed or administered properly, can have life-threatening consequences. In order to combat our issues with nonadherence, a PAH self-care responsibilities contract was developed and used with all patients on therapy for PAH. The overall outcome of developing and implementing the self-care agreement was positive for our program, which subsequently narrowed the knowledge gap that existed regarding the PAH plan of care. By narrowing the gap, we were able to combat our challenges with nonadherence and ultimately improve the success of our patients' PAH treatment regimens.

#### References

1. Jimmy B, Jose J. Patient medication adherence: measures in daily practice. *Oman Med J.* 2011;26(3):155-159. doi:10.5001/omj.2011.38.
2. Martin LR, Williams SL, Haskard KB, DiMatteo MR. The challenge of patient adherence. *Ther Clin Risk Manag.* 2005;1(3):189-199.
3. Tobin DG, Keough Forte K, Johnson McGee S. Breaking the pain contract: a better controlled-substance agreement for patients on chronic opioid therapy. *Cleve Clin J Med.* 2016;83(11):827-835.

**Beaumont**

**Pulmonary Arterial Hypertension (PAH) Self Care Management Responsibilities and Plan**

The effectiveness and safety of pulmonary arterial hypertension (PAH) management depends on a collaborative approach between the patient and the multidisciplinary team. My PAH management team has educated me in regards to the PAH disease process, classification, testing, and treatment in order for me to manage PAH daily.

I, \_\_\_\_\_, understand and agree that the following are my self care responsibilities as a patient of the Beaumont Pulmonary Hypertension Center:

1. I will notify the Pulmonary Hypertension Center in advance of any planned tests, procedures, or surgeries in order to receive instructions for care.
2. If I am on intravenous or subcutaneous drug therapy for pulmonary arterial hypertension, I agree to carry my back up medication, back up pump, and supplies with me at all times.
3. I agree to carry the emergency card provided by the Pulmonary Hypertension Center.
4. I agree to notify all other healthcare providers of my diagnosis of pulmonary arterial hypertension and any pulmonary arterial hypertension medications I am taking.
5. I agree to notify the Pulmonary Hypertension Center of any and all medications I take, including prescription medications, over the counter medications, vitamins, and herbal supplements.
6. If I am female, I understand the increased risk pregnancy places on myself and the unborn child. I understand that I must not become pregnant. I agree to utilize 2 forms of contraception or have an intrauterine device placed.
7. I agree to have laboratory testing completed as ordered by the PAH management team.
8. The risks of smoking have been explained to me. I agree to abstain from smoking cigarettes, pipes, cigars, or inhaling any substance into my lungs.
9. I agree to abstain from illicit drug use such as cocaine and methamphetamines.
10. I agree to follow a 2 gram sodium diet.
11. I have been instructed on the importance of using oxygen and agree to follow my written plan.
12. I agree to avoid NSAIDS (non-steroidal anti-inflammatory drugs like Motrin, Aleve, etc.) and nasal/oral decongestants containing pseudoephedrine.
13. I agree to take my PAH medications daily and will not stop taking the medications for any reason unless directly instructed to do so by my pulmonary hypertension physician.
14. I have been instructed on the risks and potential side effects of the pulmonary arterial hypertension medications.

I understand the above and agree to follow this plan

Signature

\_\_\_\_\_

Printed Name

\_\_\_\_\_

Witness

\_\_\_\_\_

Date

\_\_\_\_\_

**Advances in**

**Pulmonary Hypertension**

Pulmonary Hypertension Association

801 Roeder Road, Suite 1000

Silver Spring, MD 20910-4496

***Advances in Pulmonary Hypertension***  
**now available online only**

*Advances in Pulmonary Hypertension* is now exclusively available at [www.AdvancesinPH.org](http://www.AdvancesinPH.org). Be sure that you have registered for a free account to **receive each issue alert and Table of Contents right in your inbox!** Additionally, the benefits of registering include:

- Ability to share articles easily with your peers around the globe.
- Creating a Favorites list down to the article level for those articles you frequently refer to.
- Viewing abstracts and exporting citations easily.

**Don't miss an issue. Register today at [www.AdvancesinPH.org](http://www.AdvancesinPH.org).**